



**PATIENT PRESENTING CLINICAL SIGNS**

**Bodhi Terhaar** Coughing on going since Aug, nervous and aggressive so gets atrevet to come in for appointments, suspect collapsing trachea, coughing getting worse

**SPECIES RADIOGRAPHIC STUDY OF THE THORAX**

**Canine** Right/left lateral and ventrodorsal views of the thorax totaling 3 images available for review.

**RADIOGRAPHIC FINDINGS**

**BREED** Moderate collapse of the cervical trachea is seen starting approximately 3.5 cm caudal to the larynx and extending up to the level of the thoracic inlet.

**Shiba Inu**

The degree of pulmonary inflation is fair. Far cranial excursion of the diaphragm is seen. There is a mild generalized bronchial lung pattern.

**SEX**

**MN**

The cardiac silhouette presents within normal limits. The vertebral heart score is 10.

Mild generalized enlargement of the liver and aerophagia are noted.

**AGE**

**13 Years**

**RADIOGRAPHIC DIAGNOSIS**

**INTERPRETED BY**

**Nele Eley, DVM**  
Dr. med. Vet. DipECVDI

- Dynamic tracheal disease.
- Mild generalized bronchial lung pattern.
- Aerophagia.
- Mild hepatomegaly

**HOSPITAL NAME**

**Sylvan Lake**  
Veterinary Clinic

**INTERPRETATION OF THE FINDINGS & FURTHER RECOMMENDATIONS**

The radiographic study confirms the presence of dynamic tracheal disease affecting mainly the cervical trachea. A mild concurrent generalized bronchial lung pattern is noted which may well be within age related normal limits and enhanced by the rather fair degree of pulmonary inflation. However, chronic irritant bronchitis, eosinophilic bronchopneumopathy, or infectious bronchitis cannot be ruled out entirely. Further evaluation of the upper and lower airways by means of endoscopy could be considered. The far cranial excursion of the diaphragm supports the presence of restriction of the upper airways.

**REFERRING VET**

**Dr. Sandy Jameson**

Differential diagnosis for the hepatomegaly, which is mild, includes vacuolar, metabolic, endocrine hepatopathy or diffuse inflammatory/infectious or neoplastic infiltrate. Correlation with the laboratory values recommended.

**INVOICE**

**56058**

**DATE**

**1-9-23**



**PATIENT**

Bodhi Terhaar

**SPECIES**

Canine

**BREED**

Shiba Inu

**SEX**

MN

**AGE**

13 Years

**INTERPRETED BY**

Nele Eley, DVM  
Dr. med. Vet. DipECVDI

**HOSPITAL NAME**

Sylvan Lake  
Veterinary Clinic

**REFERRING VET**

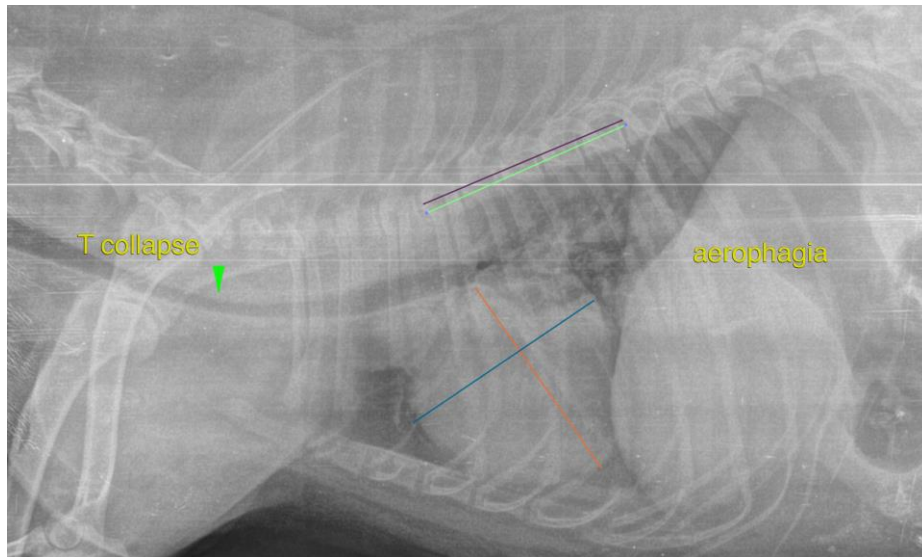
Dr. Sandy Jameson

**INVOICE**

56058

**DATE**

1-9-23



The information and recommendations provided are based on the images presented by the referring veterinarian/sonographer. No evaluation can be communicated regarding pathology that was not visible in the image/video clips provided.

Thank you for this referral. If the clinical or image interpretation does not parallel your findings or if I can be of any further assistance please contact me.

**Nele Eley**, DVM, Dr. med. vet., DipECVDI  
European Specialist in Veterinary Diagnostic Imaging, Cert. Radiology,  
Senior lecturer University of Giessen, Germany, Veterinary Faculty, Department of Radiology  
Nele.Eley@sonopath.com