



PATIENT

Brantley Fedak

SPECIES

Canine

BREED

Staffordshire Mix

SEX

NM

AGE

9Y

WEIGHT

73lbs

INTERPRETED BY

Nele Eley (Ondreka),
DVM Dr. med. vet.,
DipECVDI

IMAGING PERFORMED BY

Jen Amidon

HOSPITAL NAME

The Pet Hospital of
Stratford

REFERRING VET

Dr. Bashkin

INVOICE

73246

DATE

1-8-26

PRESENTING CLINICAL SIGNS

Recheck xrays, "Complete sagittal fracture of P2 right hind digit 5 with moderate displacement" and has been in a splint for 4 weeks.

RADIOGRAPHIC STUDY OF THE RIGHT HIND PAW

Mediolateral and dorsoplantar views of the right hind paw totaling 2 images available for review. Compared with prior study dated December 2025.

RADIOGRAPHIC FINDINGS

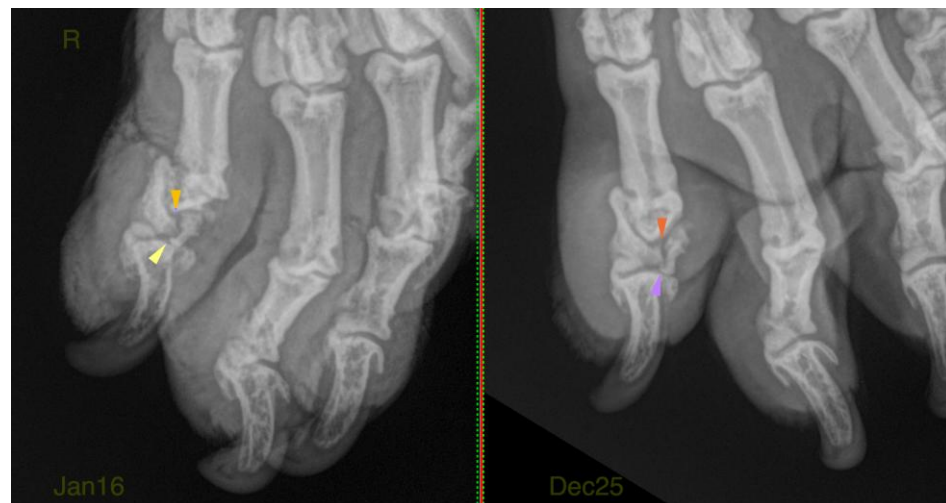
Complete sagittal fracture of the 2nd phalanx persists. Fracture line remains visible with mild rounding of margins. No further displacement is seen compared with the previous study. The alignment is maintained. Mild residual soft tissue swelling is noted; reduced compared to prior imaging. Mild peripheral new bone formation is noted. No radiopaque bridging callus is seen yet. Bones appear vital.

RADIOGRAPHIC DIAGNOSIS

- Signs of delayed union of complete sagittal fracture of the 2nd phalanx with articular surface involvement in the digit 5 of the right hind limb.

INTERPRETATION OF FINDINGS & FURTHER RECOMMENDATIONS

The fracture demonstrated stable position with early signs of peripheral new bone formation, but no definitive osseous healing is seen yet. The persistence of a visible fracture line has to be noted. Rounded fracture margins and absence of bridging callus suggest slow or incomplete osseous union. One cause of the suspect delayed union is the involvement of the proximal and distal joint surfaces. Even if the bone fragments are splinted well externally, small movements at the joint surface can occur with every step which impairs callus formation. The combination of motion and limited bone healing may result in a fibrous union rather than an osseous union.





PATIENT

Brantley Fedak

SPECIES

Canine

BREED

Staffordshire Mix

SEX

NM

AGE

9Y

WEIGHT

73lbs

INTERPRETED BY

Nele Eley (Ondreka),
DVM Dr. med. vet.,
DipECVDI

IMAGING PERFORMED BY

Jen Amidon

HOSPITAL NAME

The Pet Hospital of
Stratford

REFERRING VET

Dr. Bashkin

INVOICE

73246

DATE

1-8-26

The information and recommendations provided are based on the images presented by the referring veterinarian. No evaluation can be communicated regarding pathology that was not visible in the image/video clips provided.

Thank you for this referral. If the clinical or image interpretation does not parallel your findings or if I can be of any further assistance please contact me.

Nele Eley (Ondreka), DVM, Dr. med. vet., DipECVDI

European Specialist in Veterinary Diagnostic Imaging, Cert. Radiology,
Senior lecturer University of Giessen/Germany, Veterinary Faculty, Department of Radiology.

info@sonopath.com