



PATIENT PRESENTING CLINICAL SIGNS

Bella Garcia all in sudden semi firm right maxillary swelling just today , losing weight
 Abnormal PE/Chem/CBC/UA Results: cbc wnl chemistry : elevation of alp , amylase , lipase

SPECIES RADIOGRAPHIC STUDY OF THE HEAD

Canine Right lateral, oblique, and ventrodorsal views of the head totaling 3 images available for review. Thoracic views are available, however, read of the head was requested.

BREED RADIOGRAPHIC FINDINGS

Labrador Retriever The oblique and ventrodorsal views of the head reveal no evidence of aggressive bone lesions.

SEX

FS

There is a mineral opacity in the mandible ventral of the distal root of the triadan 309 in what is marked the “left mandible.” The cortical bone is intact. Mild widening of the periodontium of the mesial and distal roots of the triadan 309 appears to be present which is more pronounced circumferential to the distal root.

Soft tissue swelling is present in the mandibular angle.

AGE

15 Years

RADIOGRAPHIC DIAGNOSIS

- Periodontal disease with resorption accentuating the distal root of the triadan 309 with apical hypercementosis versus dystrophic mineralization.
- Soft tissue swelling in the mandibular angle.

INTERPRETED BY

Nele Eley, DVM
 Dr. med. Vet. DipECVDI

INTERPRETATION OF THE FINDINGS & FURTHER RECOMMENDATIONS

Regional hypercementosis or dystrophic mineralization appear to be present ventral of the distal root of the triadan 309 which reveals evidence of periodontal disease. No overall enlargement of the mandibular diameter is seen at the same level and there is no evidence of aggressive bone lesions identified in the radiographs.

HOSPITAL NAME

Samuel Gabriel

The soft tissue swelling in the mandibular angle is in the position of the submandibular lymph nodes and may represent lymphadenomegaly. However, soft tissue swelling of other origin cannot be ruled out. Consider fine needle aspiration for further definition and the patient may benefit from a CT study of the head should there be clinically palpable swelling that is not evident radiographically.

REFERRING VET

Gabriel

INVOICE

49401

DATE

1-8-22



PATIENT

Bella Garcia

SPECIES

Canine

BREED

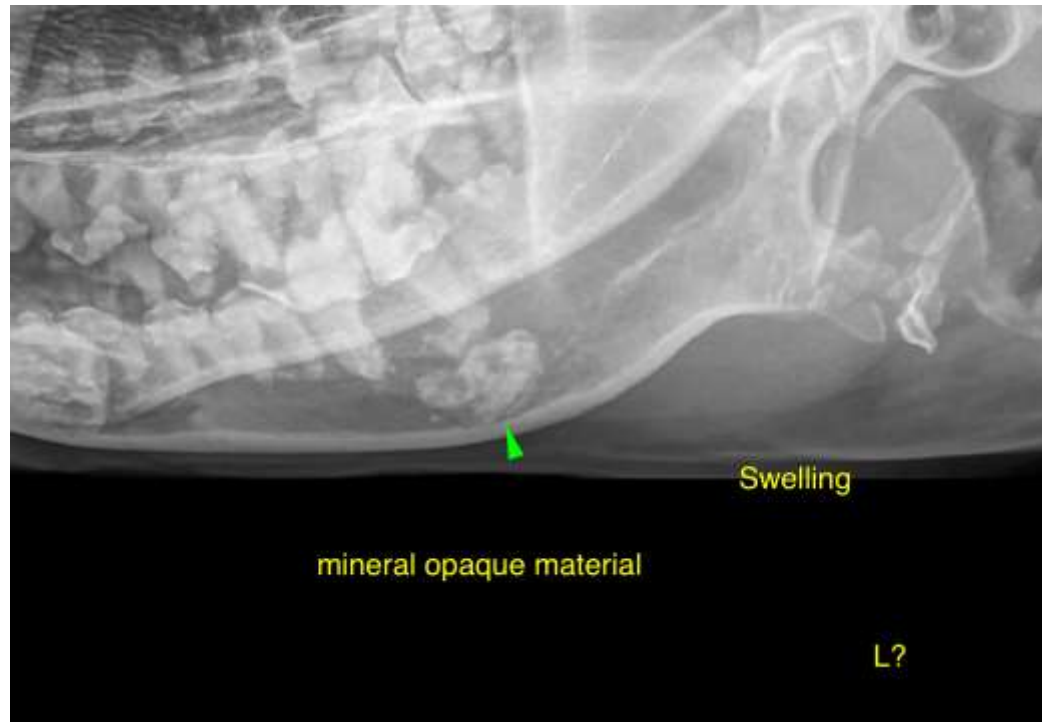
Labrador Retriever

SEX

FS

AGE

15 Years



INTERPRETED BY

Nele Eley, DVM
Dr. med. Vet. DipECVDI

The information and recommendations provided are based on the images presented by the referring veterinarian. No evaluation can be communicated regarding pathology that was not visible in the image/video clips provided.

Thank you for this referral. If the clinical or image interpretation does not parallel your findings or if I can be of any further assistance please contact me.

HOSPITAL NAME

Samuel Gabriel

Nele Eley, DVM, Dr. med. vet., DipECVDI
European Specialist in Veterinary Diagnostic Imaging, Cert. Radiology,
Senior lecturer University of Giessen, Germany, Veterinary Faculty, Department of Radiology
Nele.Eley@sonopath.com

REFERRING VET

Gabriel

INVOICE

49401

DATE

1-8-22