

**PATIENT PRESENTING CLINICAL SIGNS**

Taquito Gerhard Patient has HX of asthma and coughing, ultrasound done in 2021. Presented with coughing and labored breathing today. Cardiac US 8/2021 with Dr Johanna Frank - no CHF at that time (report can be made available if helpful)

**SPECIES RADIOGRAPHIC STUDY OF THE THORAX**

Canine Right lateral and dorsoventral views totaling 2 images available for review.

**BREED RADIOGRAPHIC FINDINGS**

Chihuahua The degree of pulmonary inflation is moderate. A moderate lobar alveolar infiltrate of the cranial and caudal subsegment of the left cranial lung lobe is seen. The remainder of the lung presents a mild generalized bronchial pattern. No evidence of mediastinal widening is seen.

**SEX** There appears to be moderate left-sided cardiomegaly with elevation of the trachea as well as broad sternal contact of the cardiac silhouette. However, no evidence of cardiogenic pulmonary edema is found.  
Male

**AGE** Gastric aerophagia is noted.

**12 Years RADIOGRAPHIC DIAGNOSIS**

- Lobar alveolar sign of the left cranial lung lobe affecting its cranial and caudal subsegments.
- No radiographic evidence of congestive heart failure
- Suspect biventricular enlargement

**INTERPRETED BY**

Nele Eley (Ondreka),  
DVM Dr. med. vet.,  
DipECVDI

**INTERPRETATION OF FINDINGS & FURTHER RECOMMENDATIONS**

Differential diagnoses include lobar pneumonia and less likely lobar neoplasia, lobar hemorrhage, or atypical presentation of non-cardiogenic pulmonary edema. The radiographic findings do not support the presence of left-sided congestive heart failure despite the presence of mild to moderate cardiomegaly with potential for biventricular enlargement.

**HOSPITAL NAME**

Harmony AH

**REFERRING VET**

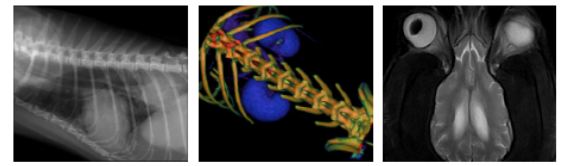
Dr. Epple

**INVOICE**

34039

**DATE**

1/7/22



**PATIENT**

Taquito Gerhard

**SPECIES**

Canine

**BREED**

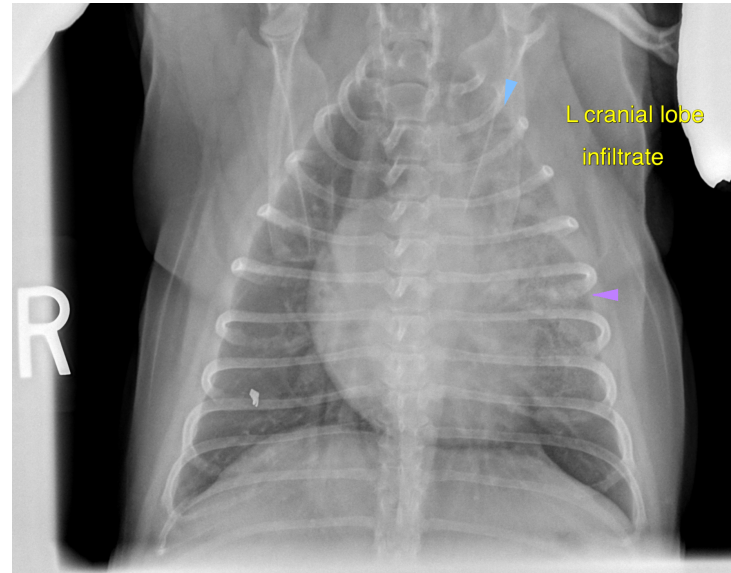
Chihuahua

**SEX**

Male

**AGE**

12 Years



The information and recommendations provided are based on the images presented by the referring veterinarian. No evaluation can be communicated regarding pathology that was not visible in the image/video clips provided.

Thank you for this referral. If the clinical or image interpretation does not parallel your findings or if I can be of any further assistance please contact me.

**INTERPRETED BY**

Nele Eley (Ondreka),  
DVM Dr. med. vet.,  
DipECVDI

**Nele Eley (Ondreka)**, DVM, Dr. med. vet., DipECVDI  
European Specialist in Veterinary Diagnostic Imaging, Cert. Radiology,  
Senior lecturer University of Giessen/Germany, Veterinary Faculty, Department of Radiology.  
Nele.Eley@sonopath.com

**HOSPITAL NAME**

Harmony AH

**REFERRING VET**

Dr. Epple

**INVOICE**

34039

**DATE**

1/7/22