



**PATIENT**

Pistol Perez

**PRESENTING CLINICAL SIGNS**

\*DVM pet. Previous CT of both elbows due to Right forelimb lameness. Pet had an arthroscopic revision of the Right elbow shortly after. Recently started limping on Left forelimb, has ulcerated skin/early lick granuloma on the anterior aspect of the Left elbow joint.

**SPECIES**

Canine

Abnormal PE/Chem/CBC/UA Results: \*DVM pet. Moderate lameness Left forelimb. ulcerated skin/early lick granuloma on the anterior aspect of the Left elbow joint.

**COMPUTED TOMOGRAPHIC STUDY OF THE SHOULDERS & ELBOWS**

**BREED**

Belgian Malinois

Plain and post contrast studies of the shoulders and post contrast study only of the elbows available for review.

**COMPUTED TOMOGRAPHIC FINDINGS**

**SEX**

Intact Male

Patient has a history of arthroscopic revision of the right elbow.

**AGE**

2 Years, 7 Months

A 6mm x 3mm sized demineralized fragment is isolated from the tip of the right medial coronoid process. The base of the right medial coronoid process presents sclerosis with loss of its trabecular bone pattern. There is a moderate amount of osteophytes at the periarticular margins. A kissing lesion with a cystic defect is seen in the medial humeral condyle and surrounded by peripheral subchondral bone sclerosis.

**INTERPRETED BY**

Nele Eley, DVM  
Dr. med. Vet. DipECVDI

Irregular outline, reduced and heterogeneous opacity with faint hypoattenuating lines are seen in the tip of the left medial coronoid process. The radioulnar incisure of the left elbow is incongruent. The subchondral bone of the medial humeral condyle is intact. Only minimal periarticular margin remodeling is seen.

Both shoulders present within normal limits.

**HOSPITAL NAME**

Mobile Pet Imaging

**COMPUTED TOMOGRAPHIC DIAGNOSIS**

- Fragmentation of the right medial coronoid process with kissing lesion of the medial humeral condyle and moderate secondary osteoarthritis.
- Medial coronoid pathology of the left elbow without overt fragmentation and with minimal secondary degenerative joint disease.

**REFERRING VET**

Meaux

**INTERPRETATION OF THE FINDINGS & FURTHER RECOMMENDATIONS**

Compared to the prior study, reduced and heterogeneous opacity are present in the tip of the left medial coronoid process as well as within the radioulnar incisure now. There is evidence of mild degenerative joint disease. The CT changes do support the presence of medial coronoid pathology with osteomalacia or fissure. An isolated fragment is not seen. Nevertheless, arthroscopic revision is recommended in presence of clinical signs for the left elbow.

**INVOICE**

49379

**DATE**

1-7-22

A large fragment is present and isolated from the tip of the right medial coronoid process. The medial humeral condyle of the right elbow presents a kissing lesion within its subchondral bone and moderate secondary osteoarthritic changes are present.



**PATIENT**

Pistol Perez

**SPECIES**

Canine

**BREED**

Belgian Malinois

**SEX**

Intact Male

**AGE**

2 Years, 7 Months

**INTERPRETED BY**

Nele Eley, DVM  
Dr. med. Vet. DipECVDI

**HOSPITAL NAME**

Mobile Pet Imaging

**REFERRING VET**

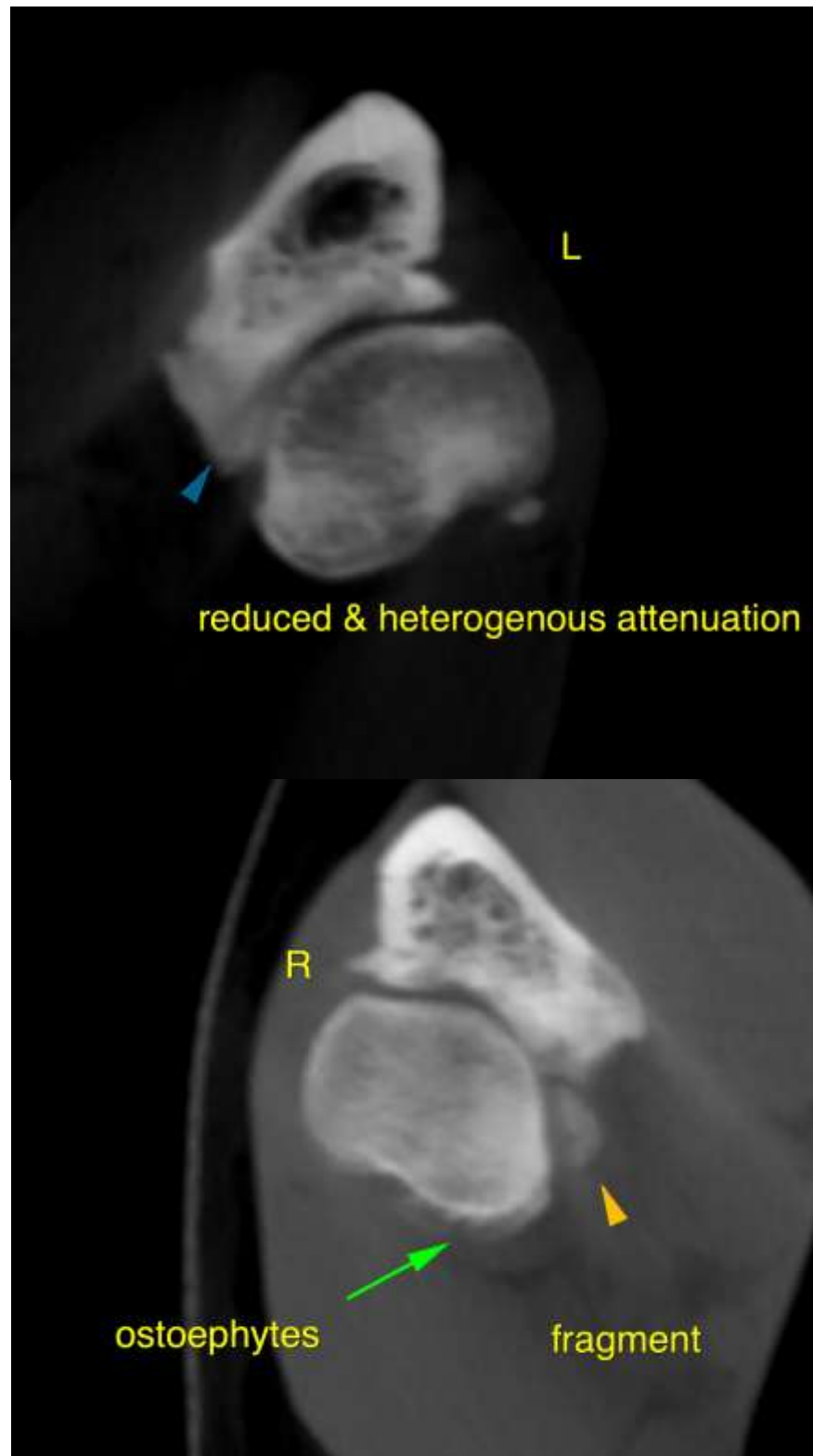
Meaux

**INVOICE**

49379

**DATE**

1-7-22





**PATIENT**

Pistol Perez

**SPECIES**

Canine

**BREED**

Belgian Malinois

**SEX**

Intact Male

**AGE**

2 Years, 7 Months

**INTERPRETED BY**

Nele Eley, DVM  
Dr. med. Vet. DipECVDI

**HOSPITAL NAME**

Mobile Pet Imaging

**REFERRING VET**

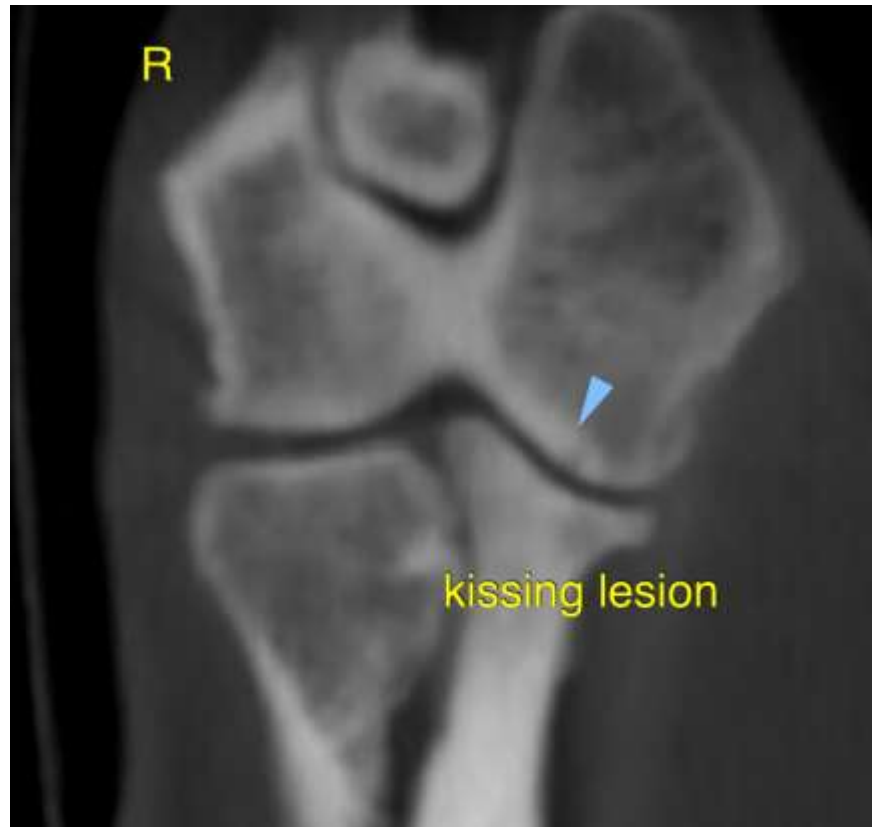Meaux

**INVOICE**

49379

**DATE**

1-7-22



The information and recommendations provided are based on the images presented by the referring veterinarian. No evaluation can be communicated regarding pathology that was not visible in the image/video clips provided.

Thank you for this referral. If the clinical or image interpretation does not parallel your findings or if I can be of any further assistance please contact me.

**Nele Eley**, DVM, Dr. med. vet., DipECVDI  
European Specialist in Veterinary Diagnostic Imaging, Cert. Radiology,  
Senior lecturer University of Giessen, Germany, Veterinary Faculty, Department of Radiology  
Nele.Eley@sonopath.com