SonoPath Teleradiology

EDUCATIONAL TELECONSULTATION SERVICES™

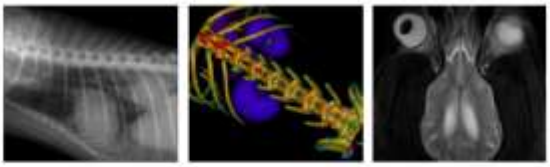

SonoPath.com
1-800-838-4268 info@sonopath.com

PATIENT

Hudson Coffin

SPECIES

Canine

BREED

Lab

SEX

MN

AGE

7 Years

INTERPRETED BY

Nele Eley, DVM
Dr. med. Vet. DipECVDI

HOSPITAL NAME

Suncoast Veterinary

REFERRING VET

Byron Young

INVOICE

49368

DATE

1-7-22

PRESENTING CLINICAL SIGNS

Hudson presents for multiple nose bleeds and upper airway dyspnea for the past two weeks. Owner reports he is also having trouble swallowing food. He is eating and no history of vomiting. Following CT, Hudson was transferred to the endoscopy suite for rhinoscopy. The nasopharyngeal region was evaluated with a flexible endoscope placed through the oral cavity. Each nasal passage was evaluated with a rigid endoscope. Swabs for bacterial and fungal culture and mucosal biopsies were collected. Dilute epinephrine drops were placed in each nostril to control minor bleeding.

COMPUTED TOMOGRAPHIC STUDY OF THE NASAL CAVITIES

Plain and post contrast studies available for review.

COMPUTED TOMOGRAPHIC FINDINGS

An irregular shaped ill-defined mineralizing mass is seen within the mid and caudal third of the left nasal cavity. The mass measures approximately 9.0 cm in length and 3.5 cm in diameter. The soft tissue component of the mass extends into and occupies the nasal fundus. Polyostotic aggressive osteolysis of the neighboring bones including the palatinal, vomer, maxillary, and nasal bones is seen.

There is periodontal disease of the triadan 208.

COMPUTED TOMOGRAPHIC DIAGNOSIS

- Mineralizing soft tissue mass with aggressive biological behavior in the left nasal cavity.
- Upper airway obstruction.
- Periodontal disease triadan 208.

INTERPRETATION OF THE FINDINGS & FURTHER RECOMMENDATIONS

The CT findings are compatible with malignant neoplasia within the left nasal cavity. Differential diagnosis includes chondrosarcoma, osteosarcoma, adenocarcinoma, other carcinoma, and other. Final diagnosis will require sampling for histology. The findings are not compatible with rhinitis and the biological behavior of the mass is considered aggressive.

SonoPath Teleradiology

EDUCATIONAL TELECONSULTATION SERVICES™

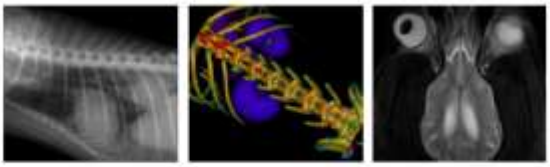

SonoPath.com
1-800-838-4268 info@sonopath.com

PATIENT

Hudson Coffin

SPECIES

Canine

BREED

Lab

SEX

MN

AGE

7 Years

INTERPRETED BY

Nele Eley, DVM
Dr. med. Vet. DipECVDI

HOSPITAL NAME

Suncoast Veterinary

REFERRING VET

Byron Young

INVOICE

49368

DATE

1-7-22

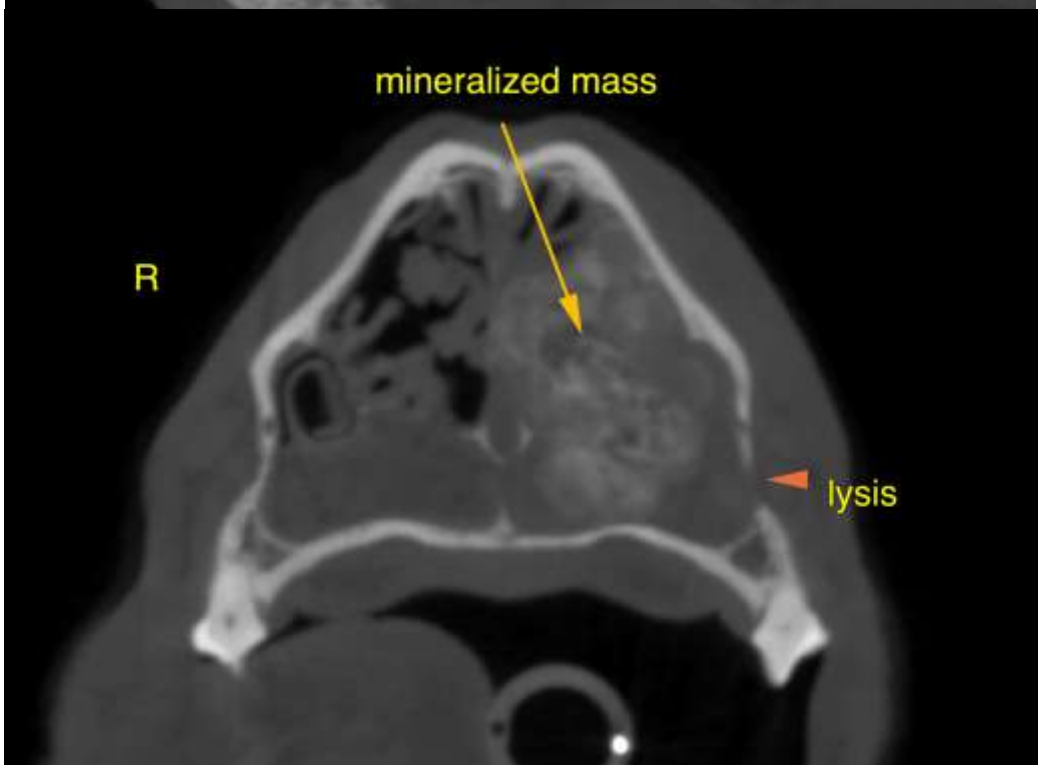

SonoPath Teleradiology

EDUCATIONAL TELECONSULTATION SERVICES™

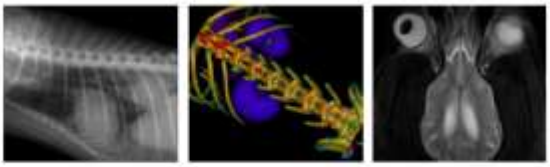

SonoPath.com
1-800-838-4268 info@sonopath.com

PATIENT

Hudson Coffin

SPECIES

Canine

BREED

Lab

SEX

MN

AGE

7 Years

INTERPRETED BY

Nele Eley, DVM
Dr. med. Vet. DipECVDI

HOSPITAL NAME

Suncoast Veterinary

REFERRING VET

Byron Young

INVOICE

49368

DATE

1-7-22

The information and recommendations provided are based on the images presented by the referring veterinarian. No evaluation can be communicated regarding pathology that was not visible in the image/video clips provided.

Thank you for this referral. If the clinical or image interpretation does not parallel your findings or if I can be of any further assistance please contact me.

Nele Eley, DVM, Dr. med. vet., DipECVDI
European Specialist in Veterinary Diagnostic Imaging, Cert. Radiology,
Senior lecturer University of Giessen, Germany, Veterinary Faculty, Department of Radiology
Nele.Eley@sonopath.com