SonoPath Teleradiology

EDUCATIONAL TELECONSULTATION SERVICES™

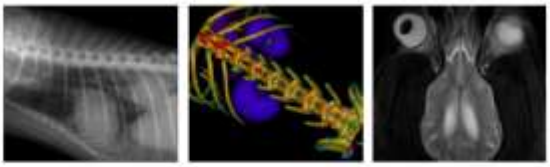

SonoPath.com
1-800-838-4268 info@sonopath.com

PATIENT

Biggie Lahaie

SPECIES

Canine

BREED

Pit Mix

SEX

Male Neutered

AGE

12 Years

INTERPRETED BY

Nele Eley, DVM
Dr. med. Vet. DipECVDI

HOSPITAL NAME

Boca Park Animal Hospital

REFERRING VET

Hill

INVOICE

49397

DATE

1-7-22

PRESENTING CLINICAL SIGNS

Acute onset of limping last night getting out of car. Grade 3-4 lame R rear with pain on extension, crepitus on flexion and cranial drawer present.

RADIOGRAPHIC STUDY OF THE STIFLES

Mediolateral views of both stifles and ventrodorsal hip extended view of the pelvis totaling 3 images available for review.

Interpretation of the stifle region requested.

RADIOGRAPHIC FINDINGS

Both stifles reveal moderate articular swelling with proximal displacement of the popliteal sesamoid bones and mild cranial thrust of the tibia.

Moderate osteoarthritic changes are present in both stifle joints which, however, appear to be more advanced in the left hind limb.

There is mild atrophy of the left hind limb musculature.

Bilateral coxofemoral osteoarthritis is present.

RADIOGRAPHIC DIAGNOSIS

- Bilateral stifle osteoarthritis with radiographic evidence of cranial cruciate ligament failure.
- Disuse atrophy of the hind limbs which is more pronounced in the left hind.

INTERPRETATION OF THE FINDINGS & FURTHER RECOMMENDATIONS

The radiographic study reveals relatively symmetric changes in both stifles. There are moderate osteoarthritic changes with articular swelling of the stifles in both hind limbs with radiographic evidence of cranial cruciate ligament failure. The osteoarthritic changes appear to be more pronounced on the left side. The disease may be longer standing in the left hind limb which is further supported by the more pronounced muscle atrophy in the left hind limb. However, part of the stifle instability may be compensated by capsular fibrosis and the clinical signs may be more severe on the right side at this point. Nevertheless, the disease should be considered bilateral.

SonoPath Teleradiology

EDUCATIONAL TELECONSULTATION SERVICES™

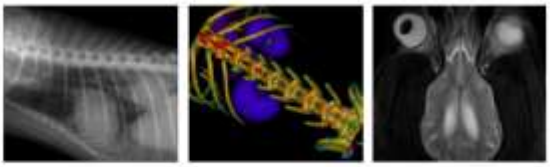

SonoPath.com
1-800-838-4268 info@sonopath.com

PATIENT

Biggie Lahaie

SPECIES

Canine

BREED

Pit Mix

SEX

Male Neutered

AGE

12 Years

INTERPRETED BY

Nele Eley, DVM
Dr. med. Vet. DipECVDI

HOSPITAL NAME

Boca Park Animal Hospital

REFERRING VET

Hill

INVOICE

49397

DATE

1-7-22

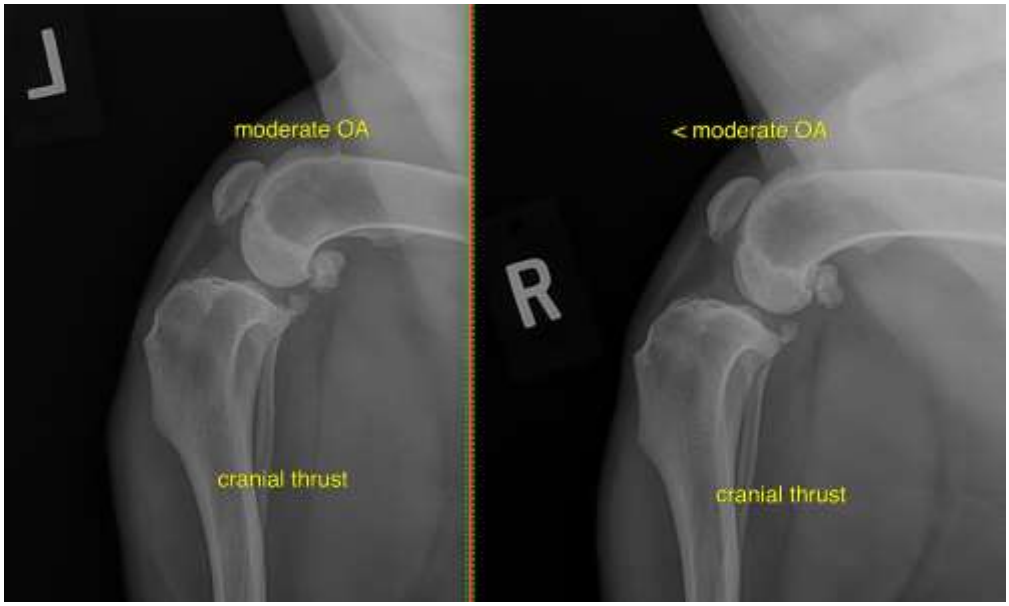

The information and recommendations provided are based on the images presented by the referring veterinarian. No evaluation can be communicated regarding pathology that was not visible in the image/video clips provided.

Thank you for this referral. If the clinical or image interpretation does not parallel your findings or if I can be of any further assistance please contact me.

Nele Eley, DVM, Dr. med. vet., DipECVDI
European Specialist in Veterinary Diagnostic Imaging, Cert. Radiology,
Senior lecturer University of Giessen, Germany, Veterinary Faculty, Department of Radiology
Nele.Eley@sonopath.com