

## PATIENT

Liam Goguen

## SPECIES

Canine

## BREED

Pug

## SEX

Male Castrated

## AGE

3.5Y

## WEIGHT

9.5kg

## INTERPRETED BY

Nele Eley (Ondreka),  
DVM Dr. med. vet.,  
DipECVDI

## IMAGING PERFORMED BY

Christine Hanney

## HOSPITAL NAME

Westford Veterinary  
Emergency and Referral  
Center

## REFERRING VET

Leah Young

## INVOICE

73190

## DATE

1-6-26

## PRESENTING CLINICAL SIGNS

Serous to mucoid nasal discharge noted in early December with increase in sneezing and stertor. Thoracic radiographs showed no obvious changes - mild narrowing of tracheal with possible tracheal collapse, Resp PCR panel positive for Mycoplasma; treated with doxycycline, Amoxi/Clav, anti-histamine - lack of improvement; discharge slightly worse on right, but bilateral; surgery to widen nares in the past

Abnormal PE/Chem/CBC/UA Results: PE: BAR, moderate stertor, foamy discharge from both nostrils (Rt>Lt); referred upper airway noise on pulmonary auscultation, LNs palpate normally; moderate dental calculus with generalized wear and some fractures/chips; otherwise PE unremarkable; CBC - mild monocytosis, Chem - mildly elevated ALP

## COMPUTED TOMOGRAPHIC STUDY OF THE HEAD

Plain and post contrast studies are available for review.

## COMPUTED TOMOGRAPHIC FINDINGS

Bilateral dentigerous cysts arising from the maxillae are seen occupying part of the right and left nasal cavities. The right cyst occupies approximately two-thirds of the right nasal cavity with severe thinning of the palatal bone. The left cyst occupies approximately one-third of the left nasal cavity with moderate palatal bone thinning. An ectopic tooth, likely the 107, is located dorsally within the right cyst. The cysts have thin smooth walls without aggressive bone destruction and hypoattenuating contrast negative content. The right cyst involves the roots of the teeth 105 and 106; the left cyst - the roots of the 205 and 206.

207 is absent.

Additional dental findings are periodontitis of the triadan 104 and small apical root abscess of the 302 with signs of periodontitis as well as crown fracture of the 404.

Long and thick hard palate consistent with brachycephalic anatomy is noted.

Tracheal hypoplasia of the cervical trachea is present.

Mild generalized thickening of the laryngeal soft tissues is noted.

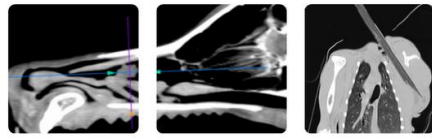
The regional lymph nodes are unremarkable.

## COMPUTED TOMOGRAPHIC DIAGNOSIS

- Bilateral maxillary dentigerous cysts with expansion into the nasal cavities.
- Dental Pathology: Roots of multiple teeth incorporated into the cysts and additional periodontitis 104, root abscess 302, and crown fracture 404.
- Brachycephalic obstructive airway presentation.

## INTERPRETATION OF FINDINGS & FURTHER RECOMMENDATIONS

The main finding is presence of bilateral maxillary dentigerous cysts with expansion and partial obstruction of the nasal cavities. The right cyst is more extensive involving two-thirds of the right nasal cavity and associated with an ectopic tooth, likely the 107. The left cyst is mildly smaller occupying part of the left nasal cavity. The cysts are thin walled and non-aggressive but cause significant bilateral palatal bone thinning.



## PATIENT

Liam Goguen

## SPECIES

Canine

## BREED

Pug

## SEX

Male Castrated

## AGE

3.5Y

## WEIGHT

9.5kg

## INTERPRETED BY

Nele Eley (Ondreka),  
DVM Dr. med. vet.,  
DipECVDI

## IMAGING PERFORMED BY

Christine Hanney

## HOSPITAL NAME

Westford Veterinary  
Emergency and Referral  
Center

## REFERRING VET

Leah Young

## INVOICE

73190

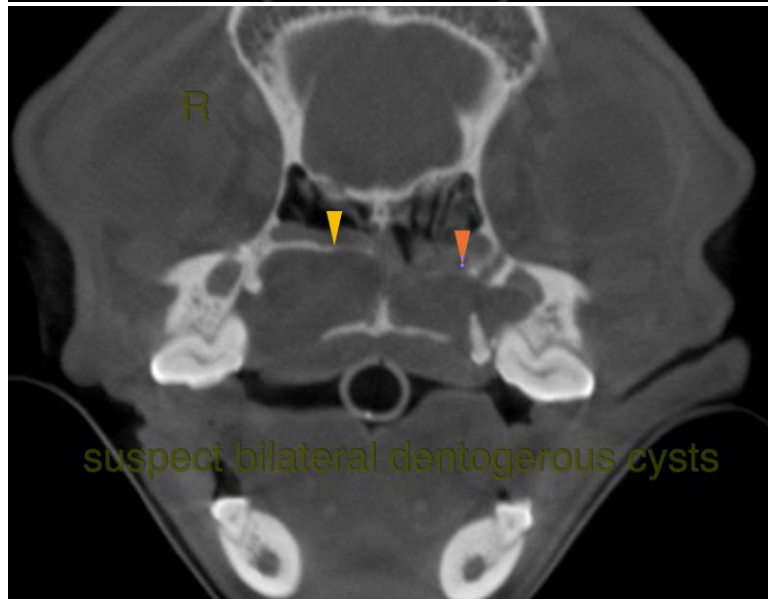
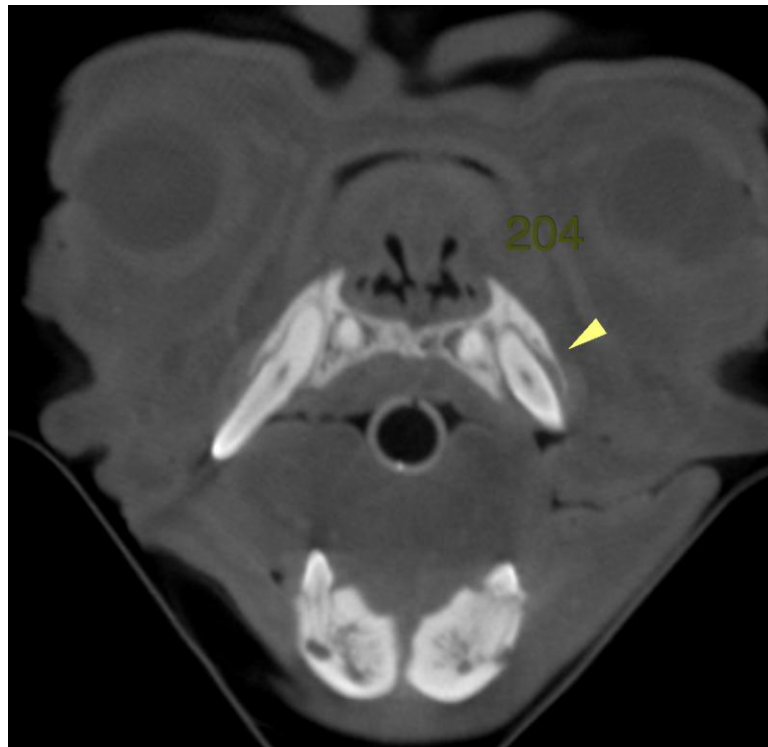
## DATE

1-6-26

Consider surgical removal of the dentigerous cysts with consecutive histopathologic examination as well as palatal reconstruction.

Dental evaluation and treatment of the additionally affected teeth is recommended as well.

Note the presence of an ectopic tooth in the dorsal aspect of the right dentigerous cyst.





## PATIENT

Liam Goguen

## SPECIES

Canine

## BREED

Pug

## SEX

Male Castrated

## AGE

3.5Y

## WEIGHT

9.5kg

## INTERPRETED BY

Nele Eley (Ondreka),  
DVM Dr. med. vet.,  
DipECVDI

## IMAGING PERFORMED BY

Christine Hanney

## HOSPITAL NAME

Westford Veterinary  
Emergency and Referral  
Center

## REFERRING VET

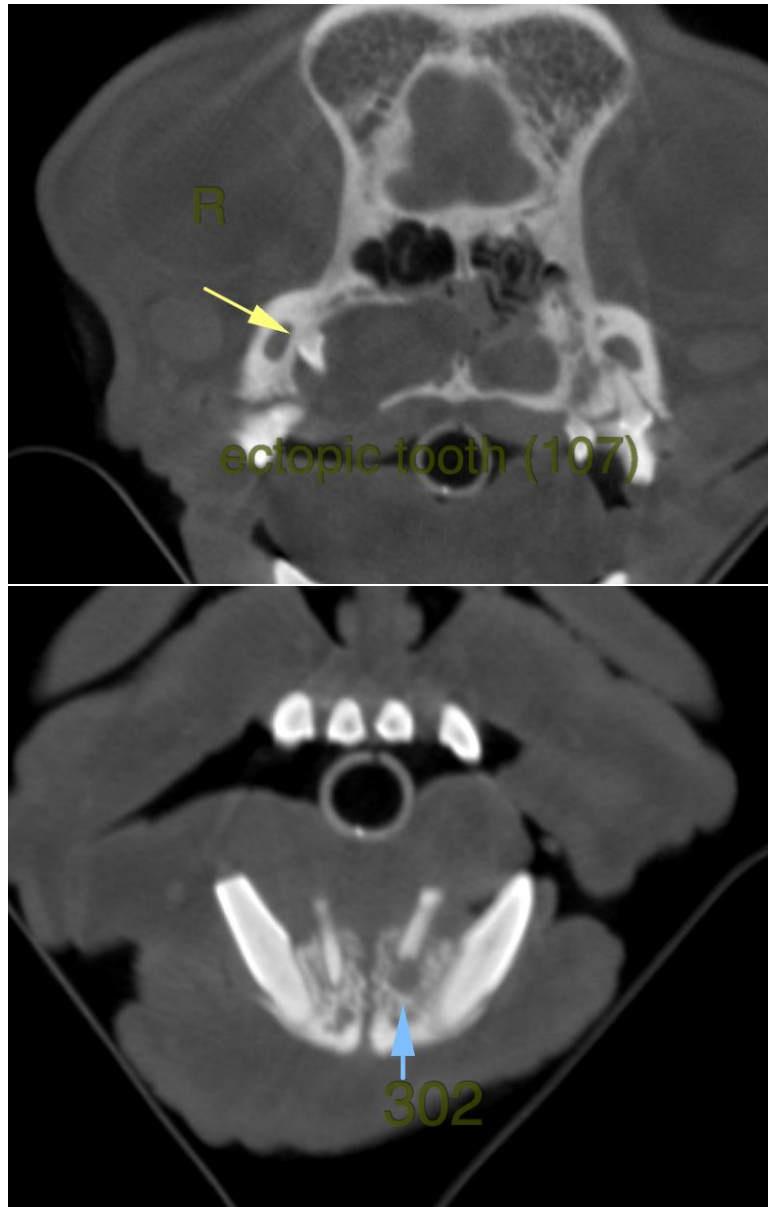
Leah Young

## INVOICE

73190

## DATE

1-6-26





## PATIENT

Liam Goguen

## SPECIES

Canine

## BREED

Pug

## SEX

Male Castrated

## AGE

3.5Y

## WEIGHT

9.5kg

## INTERPRETED BY

Nele Eley (Ondreka),  
DVM Dr. med. vet.,  
DipECVDI

## IMAGING PERFORMED BY

Christine Hanney

## HOSPITAL NAME

Westford Veterinary  
Emergency and Referral  
Center

## REFERRING VET

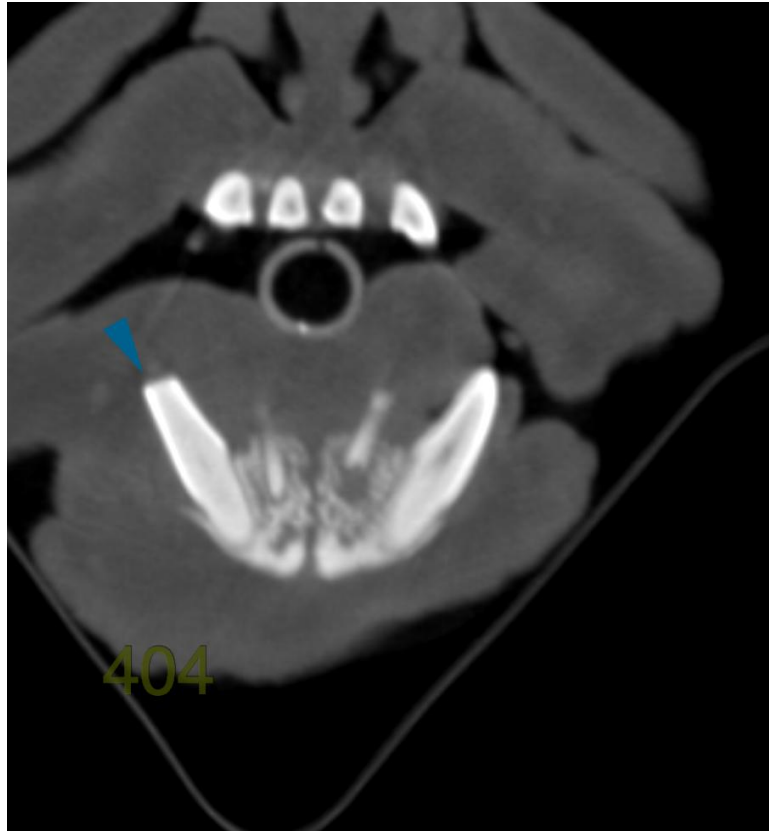Leah Young

## INVOICE

73190

## DATE

1-6-26



The information and recommendations provided are based on the images presented by the referring veterinarian. No evaluation can be communicated regarding pathology that was not visible in the image/video clips provided.

Thank you for this referral. If the clinical or image interpretation does not parallel your findings or if I can be of any further assistance please contact me.

**Nele Eley (Ondreka)**, DVM, Dr. med. vet., DipECVDI  
European Specialist in Veterinary Diagnostic Imaging, Cert. Radiology,  
Senior lecturer University of Giessen/Germany, Veterinary Faculty, Department of Radiology.  
[info@sonopath.com](mailto:info@sonopath.com)