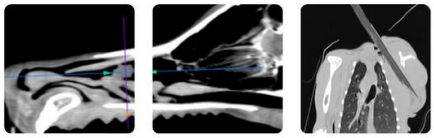

Teleradiology
Educational Teleconsultation Services™

PATIENT
Ellie Reiswig

SPECIES
Feline

BREED
Domestic Shorthair

SEX
FS

AGE
11Y

WEIGHT
10.2lbs

INTERPRETED BY
Nele Eley (Ondreka), DVM Dr. med. vet., DipECVDI

IMAGING PERFORMED BY
Bailey and Amanda

HOSPITAL NAME
Casselton Vet Service

REFERRING VET
Jackie Schmid

INVOICE
73186

DATE
1-6-26

PRESENTING CLINICAL SIGNS

Chronic ear bilateral ear infections over the last couple of months that have not been resolving. Physical exam findings / DDx on 12/30/25: Left ear - Polyp/Neoplasia? Right ear - Neoplasia? Space occupying lesion that is causing pain when the cat's mouth is open.

COMPUTED TOMOGRAPHIC STUDY OF THE HEAD

Plain and post contrast studies are available for review.

COMPUTED TOMOGRAPHIC FINDINGS

The CT study reveals a large, ill-defined, soft tissue attenuating mass extending ventral to the right external auditory meatus. Size is approximately 20 x 25mm. The mass presents marked and severe heterogeneous contrast enhancement. Multiple internal cavitations with fluid attenuating central components are seen. Multiple superficial vessels are present adjacent to and within the mass. The mass appears to connect with the lumen of the right external auditory meatus which is obliterated and expanded by the mass. Part of the residual lumen contains fluid attenuating material. The right tympanic bulla is fluid filled consistent with extension of adjacent disease. The mass presents no clear association with the salivary glands or lymph nodes. Aggressive osteolytic changes are not seen at this point.

The right retropharyngeal and parotid lymph nodes are mildly enlarged.

The left ear canal and tympanic bulla present within normal limits.

COMPUTED TOMOGRAPHIC DIAGNOSIS

- Large aggressive appearing soft tissue mass associated with the right external ear canal.
- Secondary right sided otitis media.
- Mild lymphadenomegaly of the right parotid and retropharyngeal lymph nodes.

INTERPRETATION OF FINDINGS & FURTHER RECOMMENDATIONS

The CT study reveals a large soft tissue mass with presumed aggressive biological behavior within and ventral to the right external auditory meatus. The findings are most consistent with neoplasia such as ceruminal gland carcinoma, squamous cell carcinoma, or other malignancy. Severe inflammatory disease with chronic periauricular abscessation and neovascularization is considered by far less likely but cannot be entirely excluded. Tissue sampling of the mass is recommended for definitive diagnosis if not performed already.

Cytology of the enlarged regional lymph nodes could be considered as well.

SonoPath
FOSTERING THE ART OF VETERINARY MEDICINE™

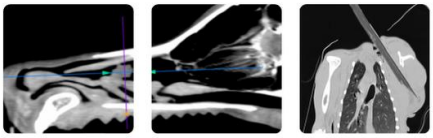

Teleradiology
Educational Teleconsultation Services™

SonoPath.com info@sonopath.com 1.800.838.4268

PATIENT

Ellie Reiswig

SPECIES

Feline

BREED

Domestic Shorthair

SEX

FS

AGE

11Y

WEIGHT

10.2lbs

INTERPRETED BY

Nele Eley (Ondreka), DVM Dr. med. vet., DipECVDI

IMAGING PERFORMED BY

Bailey and Amanda

HOSPITAL NAME

Casselton Vet Service

REFERRING VET

Jackie Schmid

INVOICE

73186

DATE

1-6-26

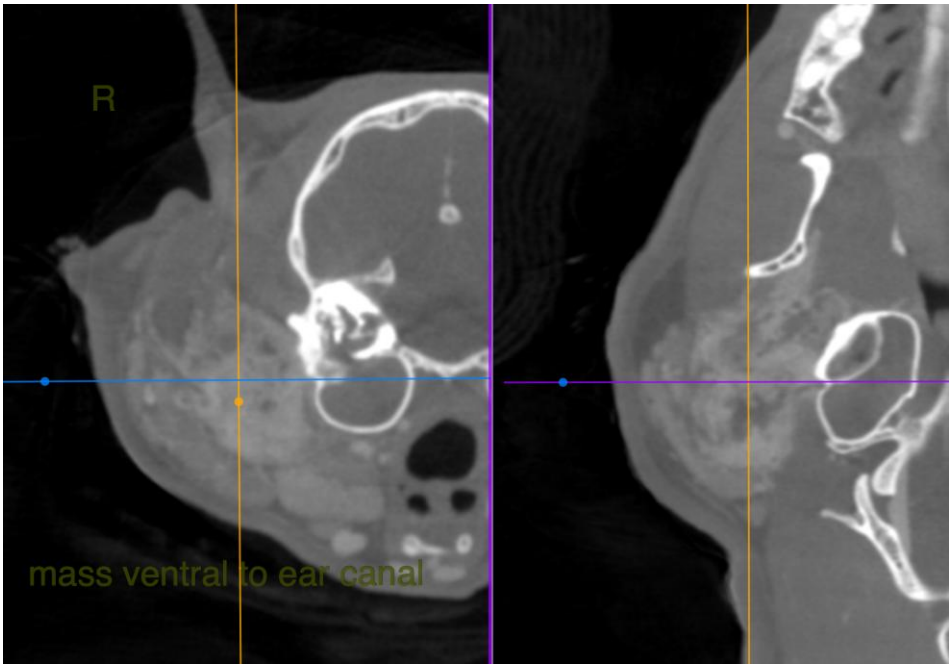

The information and recommendations provided are based on the images presented by the referring veterinarian. No evaluation can be communicated regarding pathology that was not visible in the image/video clips provided.

Thank you for this referral. If the clinical or image interpretation does not parallel your findings or if I can be of any further assistance please contact me.

Nele Eley (Ondreka), DVM, Dr. med. vet., DipECVDI
European Specialist in Veterinary Diagnostic Imaging, Cert. Radiology,
Senior lecturer University of Giessen/Germany, Veterinary Faculty, Department of Radiology.
info@sonopath.com