



**PATIENT PRESENTING CLINICAL SIGNS**

Sugar Schwartz Liver mass- suspect hepatocellular carcinoma based on FNA cytology. Splenic aspirate was inconclusive. CT for surgical planning  
Abnormal PE/Chem/CBC/UA Results: Obese

**SPECIES COMPUTED TOMOGRAPHIC STUDY OF THE ABDOMEN**

Canine Plain and post-contrast studies available for review.

**BREED COMPUTED TOMOGRAPHIC FINDINGS**

Retriever X Both coxofemoral joints present mild osteoarthritis changes.

**SEX**

Spayed Female Both kidneys present within normal limits for size, shape and organ architecture. After contrast administration a bilaterally symmetric and uniform nephro- and pyelogram is noted.

**AGE**

11 Years The adrenal glands are within normal limits for size, shape and organ architecture.

An 8.0 cm sized expansile mass with heterogeneous enhancement is seen in the left lateral liver lobe. Small hypoenhancing nodules are distributed throughout the remainder of the liver parenchyma. A single small parenchymal cyst is seen in the left division of the liver. The gallbladder is moderately distended. Mild focal polypoid hyperplasia of the gallbladder lining is seen.

**INTERPRETED BY**

Nele Eley (Ondreka),  
DVM Dr. med. vet.,  
DipECVDI

Multiple small hyperenhancing nodules are present within the spleen.

The pancreas is evenly contoured, the pancreatic parenchyma is homogeneous and presents uniform contrast enhancement.

**HOSPITAL NAME**

Mobile Pet Imaging

The position, delineation, wall and content of the gastrointestinal tract are considered within normal limits throughout.

**COMPUTED TOMOGRAPHIC DIAGNOSIS**

**REFERRING VET**

Dr. Meaux

- Expansile left lateral liver lobe mass with heterogeneous enhancement
- Multiple hepatic and splenic nodules

**INTERPRETATION OF FINDINGS & FURTHER RECOMMENDATIONS**

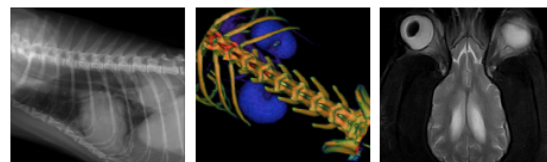
**INVOICE**

34035

**DATE**

1/6/22

Differential diagnoses for the liver mass include hepatocellular carcinoma, hepatoma, hemangiosarcoma, hemangioma, and other. Based on the clinical history, hepatocellular carcinoma appears to be the main potential. The mass is in a resectable position. The hypoenhancing nodules within the remainder of the liver parenchyma are likely to represent benign nodular hyperplasia or regenerative nodules. Metastatic disease cannot be ruled out entirely, but is thought less likely based on the CT appearance. Similar applies to the splenic nodules. Benign nodular hyperplasia and extramedullary hematopoiesis are the most likely differential diagnoses. Metastatic disease is thought less likely.



**PATIENT**

Sugar Schwartz

**SPECIES**

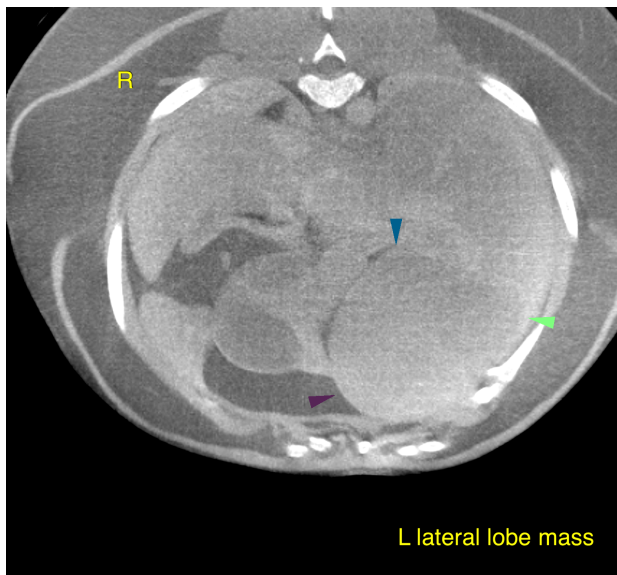
Canine

**BREED**

Retriever X

**SEX**

Spayed Female



**AGE**

11 Years

The information and recommendations provided are based on the images presented by the referring veterinarian. No evaluation can be communicated regarding pathology that was not visible in the image/video clips provided.

Thank you for this referral. If the clinical or image interpretation does not parallel your findings or if I can be of any further assistance please contact me.

**INTERPRETED BY**

Nele Eley (Ondreka),  
DVM Dr. med. vet.,  
DipECVDI

**Nele Eley (Ondreka)**, DVM, Dr. med. vet., DipECVDI  
European Specialist in Veterinary Diagnostic Imaging, Cert. Radiology,  
Senior lecturer University of Giessen/Germany, Veterinary Faculty, Department of Radiology.  
Nele.Eley@sonopath.com

**HOSPITAL NAME**

Mobile Pet Imaging

**REFERRING VET**

Dr. Meaux

**INVOICE**

34035

**DATE**

1/6/22