


**PATIENT PRESENTING CLINICAL SIGNS**

Lance Mayou Liver enlarged diffusely mottled with mass and areas of cavitation, left worse than right.

**COMPUTED TOMOGRAPHIC STUDY OF THE THORAX & ABDOMEN**

**SPECIES** Plain and post-contrast studies available for review.

Feline

**COMPUTED TOMOGRAPHIC FINDINGS**
**BREED** Abdomen

Russian Blue The serosal fat presents normal attenuation behavior. There is no evidence of peritoneal effusion or peritonitis.

Both kidneys present within normal limits for size, shape and organ architecture. After contrast administration a bilaterally symmetric and uniform nephro- and pyelogram is noted.

**SEX**

Male

The adrenal glands are within normal limits for size, shape and organ architecture.

The spleen presents normal shape, even surface, uniformly attenuating parenchyma and homogeneous contrast enhancement, unremarkable.

**AGE**

13 Years

A large, expansile, cavitating and heterogeneously enhancing mass of approximately 9.0 cm diameter is deviating the entire central and left division of the liver. A severe mass effect onto the portal vein, caudal vena cava, cystic duct and common bile duct is seen. The right division of the liver presents multiple hypoenhancing nodules. The gallbladder is mildly distended. The mass effects deviates the pancreas and the stomach.

**INTERPRETED BY**

Nele Eley (Ondreka),  
 DVM Dr. med. vet.,  
 DipECVDI

The pancreas is evenly contoured, the pancreatic parenchyma is homogeneous and presents uniform contrast enhancement.

The position, delineation, wall and content of the gastrointestinal tract are considered within normal limits throughout.

**HOSPITAL NAME**

Scottsdale Vet Clinic

Mild bilateral coxofemoral osteoarthritis is noted.

Thorax
**REFERRING VET**

Dr. Langhofer

The sternal, cranial mediastinal and tracheobronchial lymph nodes are small elongated with a normal short-to-long-axis-ratio is < 0.5, the attenuation and contrast enhancement pattern is uniform and considered within normal limits.

The cardiovascular structures including the pulmonary vasculature are within normal limits.

**INVOICE**

34037

The bronchial tree presents with regular branching and tapers uniformly towards the periphery as expected, the bronchial walls are thin and smooth. The bronchus-to-artery ratio is within normal limits.

The lung parenchyma presents the expected architecture and attenuation behavior.

**DATE**

1/6/22

Small incidental gas pockets are seen within the esophageal lumen, there is no evidence of abnormal dilation.


**PATIENT COMPUTED TOMOGRAPHIC DIAGNOSIS**

Lance Mayou

- Large cavitating and expansile mass meeting neoplastic criteria within the central and left divisions of the liver.
- Multiple hypoenhancing nodules within the remainder of the liver

**SPECIES**

Feline

**BREED**

Russian Blue

**SEX**

Male

**AGE**

13 Years

**INTERPRETED BY**

 Nele Eley (Ondreka),  
 DVM Dr. med. vet.,  
 DipECVDI

**HOSPITAL NAME**

Scottsdale Vet Clinic

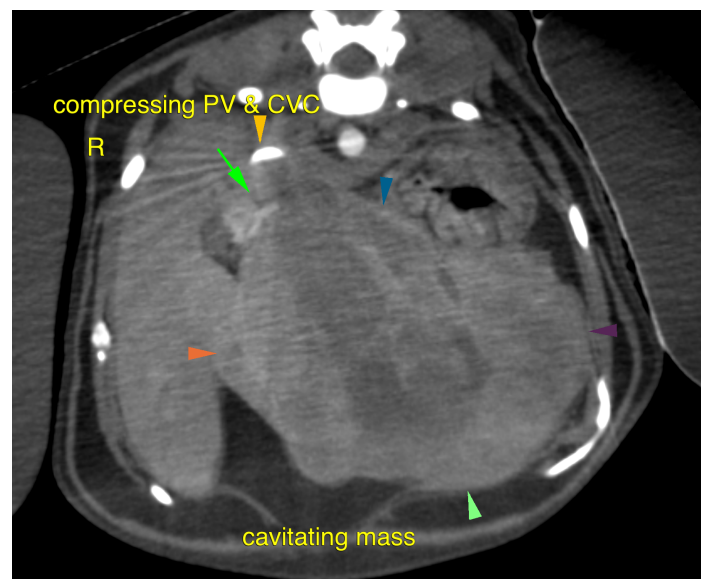
**REFERRING VET**

Dr. Langhofer

**INTERPRETATION OF FINDINGS & FURTHER RECOMMENDATIONS**

Differential diagnoses include hepatocellular or biliary carcinoma as well as adenoma, hepatoma, and secondary neoplasia of the liver. Resectability may be limited by the extensive tumor growth and involvement of critical structures in the portal hilus. Moreover, it has to be noted that hypoenhancing nodules are present in the remainder of the liver with the main differential diagnoses of benign nodular hyperplasia, multiple cystadenomas, and metastatic disease. No evidence of pulmonary or mediastinal metastatic disease noted.

Please Note: The study is left/right flipped.



The information and recommendations provided are based on the images presented by the referring veterinarian. No evaluation can be communicated regarding pathology that was not visible in the image/video clips provided.

**INVOICE**

34037

**DATE**

1/6/22

Thank you for this referral. If the clinical or image interpretation does not parallel your findings or if I can be of any further assistance please contact me.

**Nele Eley (Ondreka)**, DVM, Dr. med. vet., DipECVDI  
 European Specialist in Veterinary Diagnostic Imaging, Cert. Radiology,  
 Senior lecturer University of Giessen/Germany, Veterinary Faculty, Department of Radiology.  
 Nele.Eley@sonopath.com