


PATIENT PRESENTING CLINICAL SIGNS

Barbie Gervin Was surrendered to VAH after PPQ encounter July 2021. Now has been adopted by foster and has been intermittently lame on LFL since. When rested dog appears normal, as soon as any exercise she is lame. She had a carpal fracture as a puppy? Also wondering if a migrating quill is causing the issue as she was full of them.

SPECIES

Canine

COMPUTED TOMOGRAPHIC STUDY OF THE CARPI

Plain study of both carpi available for review.

BREED

Lab X

COMPUTED TOMOGRAPHIC FINDINGS
SEX

Spayed Female

Osseous injury of the proximal base of the 5th metacarpal bone is noted I the left front limb. There are 3 isolated rounded bone fragments of 2.5, 2.5, and 1.5 mm diameter each. A corresponding concave fragment bed is seen in the base of the 5th metacarpal bone, surrounded by medullary sclerosis. There is mild circumferential soft tissue swelling. The ulna carpal bone, radiocarpal bone, and remainder of the carpal and metacarpals present no evidence of osseous injury. The right carpus presents within normal limits. No evidence of hyperattenuating foreign material is seen in the carpal soft tissues.

AGE

1 Year 7 Months

COMPUTED TOMOGRAPHIC DIAGNOSIS

- Chronic osseous injury of the 5th metacarpal bone in the left carpus

INTERPRETATION OF FINDINGS & FURTHER RECOMMENDATIONS
INTERPRETED BY

 Nele Eley (Ondreka),
 DVM Dr. med. vet.,
 DipECVDI

The CT findings support the presence of chronic fracture in the proximal base of the 5th metacarpal bone with three small avulsion fragments in the left front limb. Trauma with ligamentous and osseous avulsion is considered most likely and may well involve the accessory metacarpal ligament. Disturbed ossification with separated ossification centers cannot be ruled out entirely, but is thought far less likely.

HOSPITAL NAME

Bridgwater VH

REFERRING VET

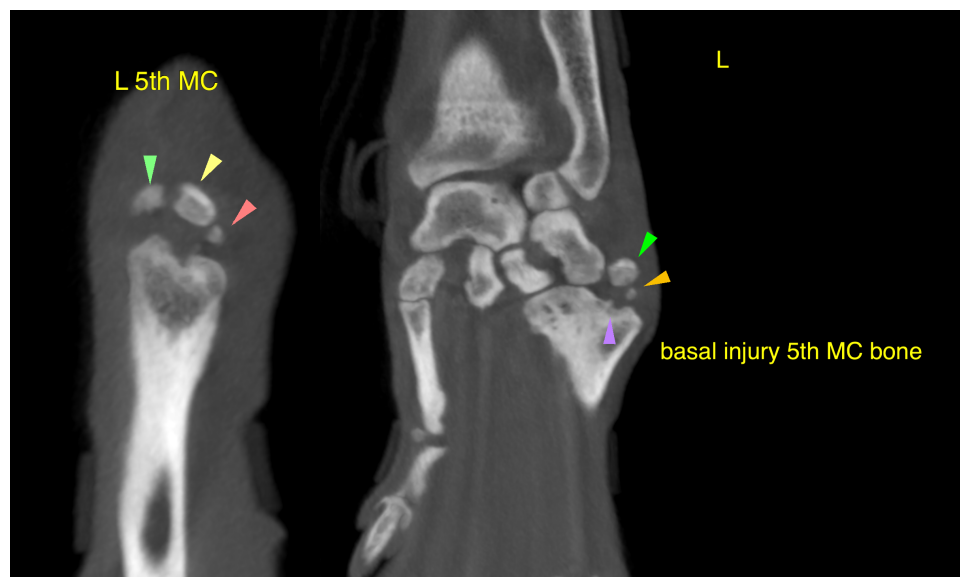
Dr. Carla Loewen

INVOICE

34034

DATE

1/6/22





PATIENT

Barbie Gervin

The information and recommendations provided are based on the images presented by the referring veterinarian. No evaluation can be communicated regarding pathology that was not visible in the image/video clips provided.

SPECIES

Canine

Thank you for this referral. If the clinical or image interpretation does not parallel your findings or if I can be of any further assistance please contact me.

BREED

Lab X

Nele Eley (Ondreka), DVM, Dr. med. vet., DipECVDI
European Specialist in Veterinary Diagnostic Imaging, Cert. Radiology,
Senior lecturer University of Giessen/Germany, Veterinary Faculty, Department of Radiology.
Nele.Eley@sonopath.com

SEX

Spayed Female

AGE

1 Year 7 Months

INTERPRETED BY

Nele Eley (Ondreka),
DVM Dr. med. vet.,
DipECVDI

HOSPITAL NAME

Bridgwater VH

REFERRING VET

Dr. Carla Loewen

INVOICE

34034

DATE

1/6/22