



PATIENT PRESENTING CLINICAL SIGNS

Stella Long Under oncology care due to soft tissue sarcoma grade 1, incomplete resection, right forelimb/ medial metatarsus. Had radiation in the past. Pet has been licking the site for several months.
Abnormal PE/Chem/CBC/UA Results: Elevated liver enzymes, liver nodules, slightly plump ilial LN on ultrasound.

SPECIES

Canine

COMPUTED TOMOGRAPHIC STUDY OF THE THORAX & ABDOMEN

Plain and post contrast studies of the abdomen and post contrast study of the thorax available for review.

BREED

Golden Mix

COMPUTED TOMOGRAPHIC FINDINGS

Thorax

SEX

Spayed Female

A small thoracic wall lipoma is seen in the right thoracic wall. A larger subcutaneous lipoma is present within the left thoracic wall.

The lung and bronchial tree present within age related normal limits.

AGE

10 Years

The mediastinal lymph nodes present within normal limits.

No evidence of cardiovascular pathology is seen.

The right axillary lymph node presents mild symmetric enlargement.

INTERPRETED BY

Nele Eley (Ondreka),
DVM Dr. med. vet.,
DipECVDI

Abdomen

Multiple mild to moderate spondyloses are seen within the thoracolumbar junction and lumbar spine. Moderate chronic intervertebral disc protrusion is noted between T13 and L1. Moderate protrusion is also present at the lumbosacral junction.

HOSPITAL NAME

Mobile Pet Imaging

The left coxofemoral joint presents moderate osteoarthritic changes. The right coxofemoral joint presents within age related normal limits.

A 12mm sized nodule is expanding the cranial pole of the left adrenal gland. The right adrenal gland presents within normal limits.

REFERRING VET

Meaux

Occasional hypoenhancing nodules are present within the liver.

A mild amount of gallbladder sludge is seen.

INVOICE

56015

There are occasional hyperenhancing nodules within the spleen.

Mild generalized thickening of the urinary bladder wall is seen.

DATE

1-5-23

The medial iliac lymph nodes and the remainder of the abdominal lymph nodes present within normal limits.



PATIENT Small areas of nodular lipomatosis are seen in the left caudodorsal abdomen and considered incidental.

Stella Long Suture material from prior celiotomy is seen in the ventral abdominal midline.

A small intramuscular lipoma is noted within the right rectus abdominus muscle.

SPECIES

The patient is mildly obese.

Canine

COMPUTED TOMOGRAPHIC DIAGNOSIS**BREED**

Golden Mix

SEX

Spayed Female

AGE

10 Years

- No evidence of pulmonary metastatic disease.
- Normal CT presentation of the mediastinal lymph nodes.
- Mild right axillary lymphadenomegaly.
- No evidence of medial iliac lymphadenomegaly or other lymphadenomegaly in the abdomen.
- Cranial pole nodule of the left adrenal gland.
- Hepatic and splenic nodules.
- Gallbladder sludge.
- Chronic cystitis pattern.
- Thoracic wall lipomas.
- Spondyloses.
- Chronic disc protrusions T13/L1, L7/S1
- Moderate left coxofemoral joint osteoarthritis.

INTERPRETATION OF FINDINGS & FURTHER RECOMMENDATIONS**INTERPRETED BY**

Nele Eley (Ondreka),
DVM Dr. med. vet.,
DipECVDI

The right axillary lymphadenomegaly is mild and the pattern suggests reactive hyperplasia. Early metastatic disease could be ruled out by means of fine needle aspiration.

There was no evidence of pulmonary metastatic disease.

The hepatic and splenic nodules are more likely to represent regenerative nodules/extramedullary hematopoiesis/benign nodular hyperplasia rather than metastatic disease even though this can never be ruled out entirely.

HOSPITAL NAME

Mobile Pet Imaging

Differential diagnosis for the cranial pole nodule within the left adrenal gland included myelolipoma, functional/ nonfunctional adenoma, adenocarcinoma, pheochromocytoma, incidentaloma, or metastases. Correlation with the laboratory values recommended.

REFERRING VET

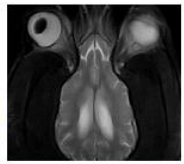
Meaux

INVOICE

56015

DATE

1-5-23



PATIENT

Stella Long

SPECIES

Canine

BREED

Golden Mix

SEX

Spayed Female

AGE

10 Years

INTERPRETED BY

Nele Eley (Ondreka),
DVM Dr. med. vet.,
DipECVDI

HOSPITAL NAME

Mobile Pet Imaging

REFERRING VET

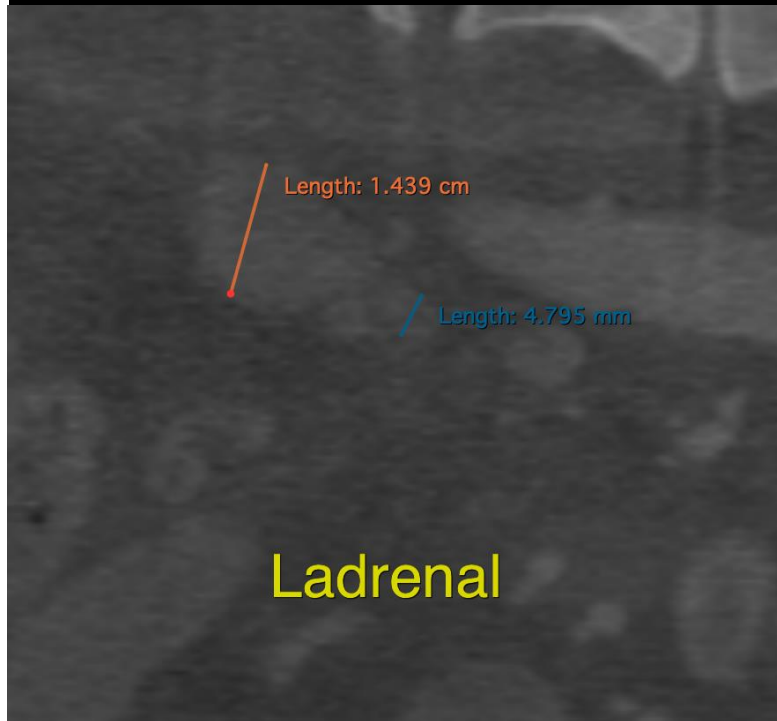
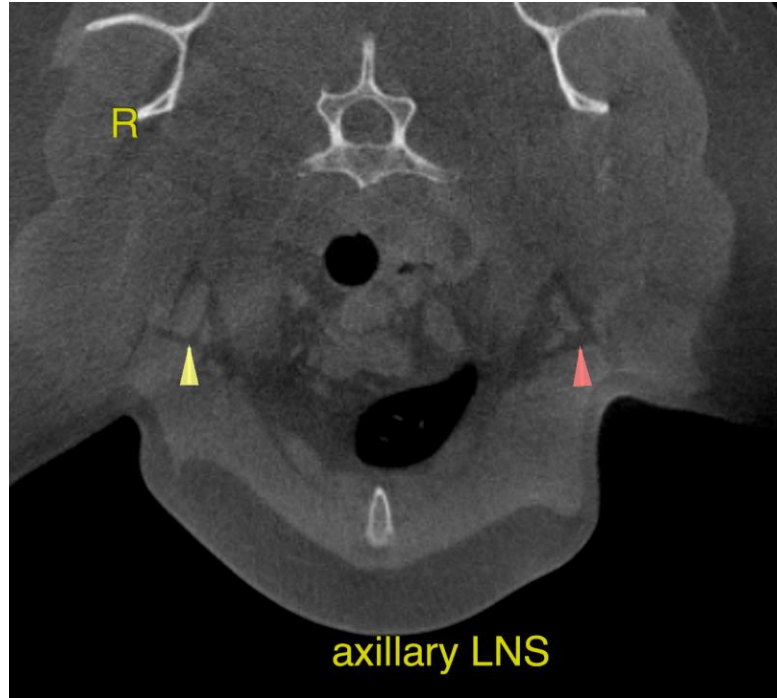
Meaux

INVOICE

56015

DATE

1-5-23





PATIENT The information and recommendations provided are based on the images presented by the referring veterinarian. No evaluation can be communicated regarding pathology that was not visible in the image/video clips provided.

Stella Long

SPECIES

Thank you for this referral. If the clinical or image interpretation does not parallel your findings or if I can be of any further assistance please contact me.

Canine

BREED

Nele Eley (Ondreka), DVM, Dr. med. vet., DipECVDI
European Specialist in Veterinary Diagnostic Imaging, Cert. Radiology,
Senior lecturer University of Giessen/Germany, Veterinary Faculty, Department of Radiology.
Nele.Eley@sonopath.com

Golden Mix

SEX

Spayed Female

AGE

10 Years

INTERPRETED BY

Nele Eley (Ondreka),
DVM Dr. med. vet.,
DipECVDI

HOSPITAL NAME

Mobile Pet Imaging

REFERRING VET

Meaux

INVOICE

56015

DATE

1-5-23