



PATIENT

Charlie McCambridge

PRESENTING CLINICAL SIGNS

Coughing and sneezing occasionally but as per O, Charlie is coughing more frequently in the last couple of days. No heart murmur, mild wheezing on oscillation.

SPECIES

Canine

RADIOGRAPHIC STUDY OF THE THORAX

Right/left lateral and ventrodorsal whole body views totaling 6 images available for review.

Thoracic read requested.

BREED

Yorkshire Terrier

RADIOGRAPHIC FINDINGS

The degree of pulmonary inflation is fair to moderate.

SEX

Neutered Male

The lung and bronchial tree present within age related normal limits.

Mild left sided cardiomegaly is noted with a vertebral heart score of 11.5 and basico-apical enlargement of the cardiac silhouette with elevated trachea as well as left atrial enlargement with bronchial splitting. No evidence of cardiogenic pulmonary edema is seen. The pulmonary vasculature presents within normal limits at this point.

AGE

5 Years

Varying degrees of cervical tracheal collapse are seen on the right and left lateral views.

No evidence of mediastinal widening is noted.

INTERPRETED BY

Nele Eley, DVM
Dr. med. Vet. DipECVDI

The thoracic boundaries present within normal limits.

RADIOGRAPHIC DIAGNOSIS

- Mild left sided cardiomegaly with left atrial enlargement and no evidence of congestive heart failure.
- Dynamic tracheal disease

HOSPITAL NAME

Truscott Animal
Hospital

INTERPRETATION OF THE FINDINGS & FURTHER RECOMMENDATIONS

The radiographic study reveals mild left sided cardiomegaly. At this time, there is no evidence of cardiogenic pulmonary edema. However, the enlarged left atrium may exert a mass effect onto the left mainstem bronchus and contribute to the coughing.

REFERRING VET

Dr. Medhat Meawad

There also is evidence of dynamic tracheal disease of the cervical trachea which may contribute to the clinical picture as well.

INVOICE

56020

Performing a full cardiac echo could be considered and airway endoscopy can be discussed as well depending on the severity of the clinical signs associated with the presumed dynamic tracheal disease.

DATE

1-5-23



PATIENT

Charlie McCambridge

SPECIES

Canine

BREED

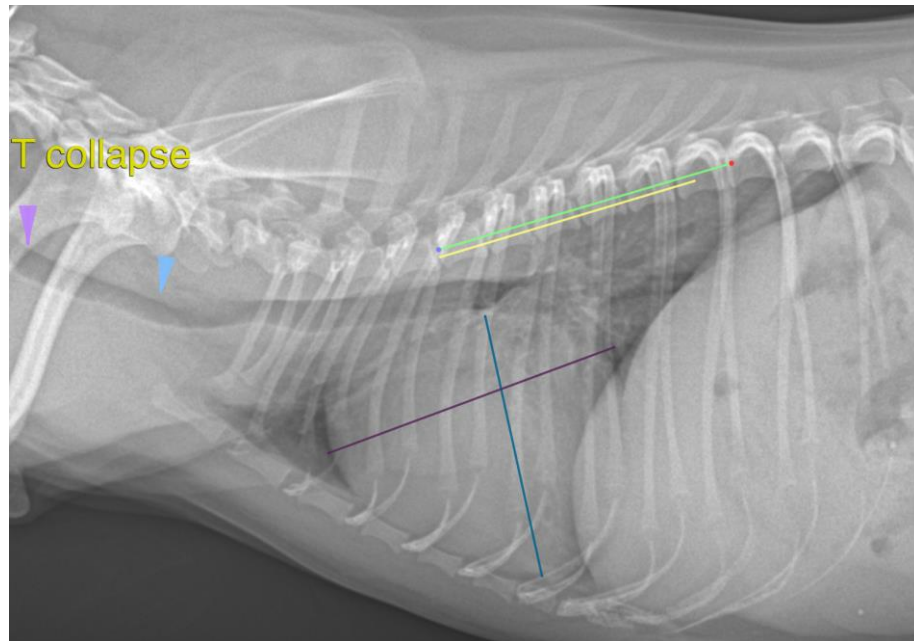
Yorkshire Terrier

SEX

Neutered Male

AGE

5 Years



INTERPRETED BY

Nele Eley, DVM
Dr. med. Vet. DipECVDI

The information and recommendations provided are based on the images presented by the referring veterinarian/sonographer. No evaluation can be communicated regarding pathology that was not visible in the image/video clips provided.

Thank you for this referral. If the clinical or image interpretation does not parallel your findings or if I can be of any further assistance please contact me.

HOSPITAL NAME

Truscott Animal
Hospital

Nele Eley, DVM, Dr. med. vet., DipECVDI
European Specialist in Veterinary Diagnostic Imaging, Cert. Radiology,
Senior lecturer University of Giessen, Germany, Veterinary Faculty, Department of Radiology
Nele.Eley@sonopath.com

REFERRING VET

Dr. Medhat Meawad

INVOICE

56020

DATE

1-5-23