



**PATIENT PRESENTING CLINICAL SIGNS**

**PATIENT** Trautman Fabbri  
**SPECIES** Presented for acute onset of coughing. P was seen initially on 12/15 for coughing. Responded well to 10 day course of doxycycline and temaril-P. Today, P has acute, goose honk/hacking cough that was first noticed this morning. P is a well regulated diabetic with KCS (regulated) and history of cataract surgery.

**SPECIES** Canine  
 Abnormal PE/Chem/CBC/UA Results: BCS 7/9, TPR = WNL, Dry hacking cough during PE. Palpation of cervical tracheal also induces coughing fit. Lungs auscult clear bilaterally, no murmur appreciated, S/S pulses

**BREED RADIOGRAPHIC STUDY OF THE THORAX**

**BREED** Shih Tzu Mix  
 Right/left lateral and ventrodorsal views totaling 3 images available for review.

**RADIOGRAPHIC FINDINGS**

**SEX** Moderate cranial and mid lumbar spondyloses are seen.

**MN** The degree of pulmonary inflation is moderate.

**AGE** The lung and bronchial tree present within age related normal limits.

8.4 The vertebral heart score is 9.5. No specific chamber enlargement is seen. There is no evidence of vascular congestion.

**INTERPRETED BY** Severe collapse of the cervical trachea is seen on the left lateral view. Milder collapse and redundant tracheal membrane are present on the right lateral view.

Nele Eley, DVM  
 Dr. med. Vet. DipECVDF  
 There is moderate gastric aerophagia.

**RADIOGRAPHIC DIAGNOSIS**

- HOSPITAL NAME** Boca Park Animal Hospital
- Dynamic tracheal disease with cervical tracheal collapse - otherwise normal age related thorax.
  - Aerophagia.
  - Spondyloses.

**REFERRING VET INTERPRETATION OF THE FINDINGS & FURTHER RECOMMENDATIONS**

**REFERRING VET** Ashman  
 The radiographic study confirms the suspicion of dynamic tracheal disease. Dynamic cervical tracheal collapse is seen which appears to correlate well with the patient's clinical signs. The radiographic presentation of the lung, bronchial tree, and the cardiovascular structures is considered within age related normal limits.

**INVOICE**

49351

**DATE**

1-5-22



**PATIENT**

Trautman Fabbri

**SPECIES**

Canine

**BREED**

Shih Tzu Mix

**SEX**

MN

**AGE**

8.4

**INTERPRETED BY**

Nele Eley, DVM  
Dr. med. Vet. DipECVDI

**HOSPITAL NAME**

Boca Park Animal  
Hospital

**REFERRING VET**

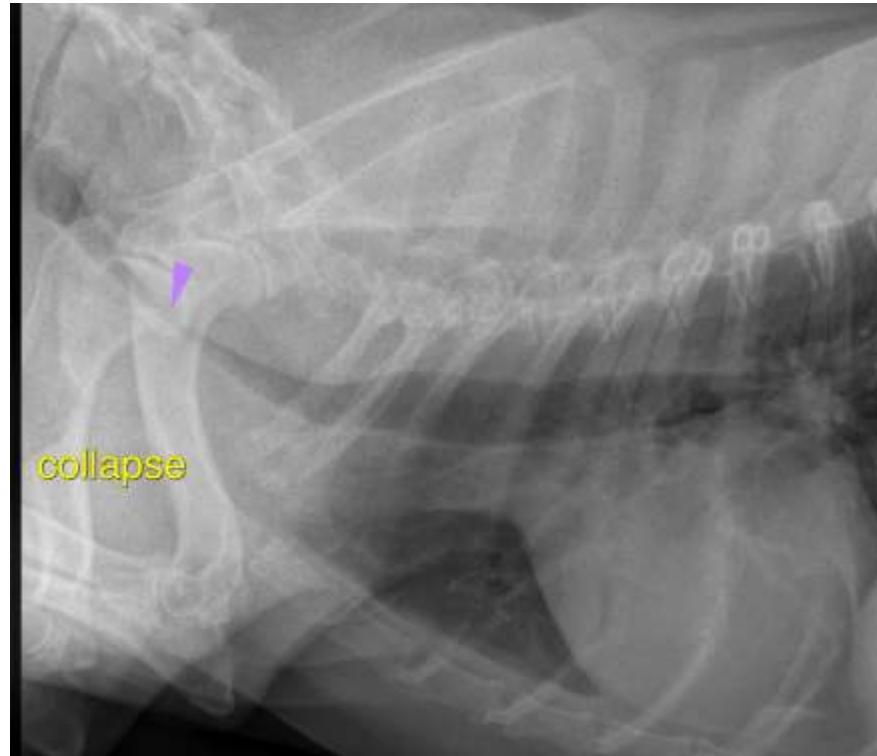
Ashman

**INVOICE**

49351

**DATE**

1-5-22



The information and recommendations provided are based on the images presented by the referring veterinarian. No evaluation can be communicated regarding pathology that was not visible in the image/video clips provided.

Thank you for this referral. If the clinical or image interpretation does not parallel your findings or if I can be of any further assistance please contact me.

**Nele Eley**, DVM, Dr. med. vet., DipECVDI  
European Specialist in Veterinary Diagnostic Imaging, Cert. Radiology,  
Senior lecturer University of Giessen, Germany, Veterinary Faculty, Department of Radiology  
Nele.Eley@sonopath.com