



PATIENT

Penny Ivory

PRESENTING CLINICAL SIGNS

O noticed P's breathing was labored, and her sides were puffing in and out. P was acting normally and E/D normally. No V/D/. This morning P had trouble swallowing but still ate and drank. O was waiting to see if it would return to normal as P was still acting like herself

SPECIES

Canine

Abnormal PE/Chem/CBC/UA Results: Penny has labored breathing, started Friday and worsened this morning, quick scan ultrasound - has fluid filled chest placed IV catheter, performed sterile chest tap and removed about 201 mls of bloody fluid O2 flow by, x-rays- has pleural fluid, large amount of digesta in stomach, blood work started no history of toxin or poisons called owner, guarded prognosis, recommend to hospitalize and have ultrasound done on Monday with Dr S, owner ok d, removed another 200 mls of bloody fluid from the chest, is breathing much better and more comfortable

BREED

Boston Terrier

COMPUTED TOMOGRAPHIC STUDY OF THE THORAX

SEX

Plain and post contrast studies available for review.

FS

COMPUTED TOMOGRAPHIC FINDINGS

T8 is a butterfly vertebra with T7/8 and T8/9 spondylosis deformans.

AGE

10 Years

A 2.0 cm sized intramuscular lipoma is seen in the left pectoralis muscle.

INTERPRETED BY

Nele Eley, DVM
Dr. med. Vet. DipECVDI

A large irregular shaped multilobulated cavitating soft tissue mass of approximately 8.0 x 4.0 cm is seen in the cranial and ventral mediastinum. The cranial mediastinal lymph nodes cannot be seen separately from this mass.

A moderate amount of fluid attenuating material is present within both pleural cavities.

HOSPITAL NAME

Mountain West
Veterinary Hospital

The lung lobe margins are retracted from the thoracic wall and rounded. Extensive atelectasis of the cranial lung lobes and right middle lobe as well as the accessory lung lobe is seen. The aerated lung presents multiple soft tissue attenuating interstitial nodules, occasional blebs and bullae, as well as multiple age related incidental pulmonary osteomas.

Multiple small hypoattenuating nodules are seen within the liver.

REFERRING VET

Andrew Burton

The full abdomen is included, however, is not part of this report.

COMPUTED TOMOGRAPHIC DIAGNOSIS

INVOICE

49352

- Cranioventral mediastinal soft tissue mass meeting neoplastic criteria.
- Multiple interstitial pulmonary nodules, bullae, and blebs.
- Bilaterally symmetric moderate pleural effusion.
- Hepatic nodules.

DATE

1-5-22

Incidental findings:

- Intramuscular lipoma - left pectoralis muscle.
- Congenital vertebral malformation.
- Spondyloses.



PATIENT

Penny Ivory

INTERPRETATION OF THE FINDINGS & FURTHER RECOMMENDATIONS

Differential diagnosis for the cranioventral mediastinal soft tissue mass includes mediastinal lymphoma, thymic lymphoma, and less likely ectopic thyroid carcinoma or thymoma.

SPECIES

Canine

The pulmonary changes are compatible with metastatic disease and should be considered so until proven otherwise.

BREED

Boston Terrier

The pleural effusion is likely to be paraneoplastic or hemorrhagic.

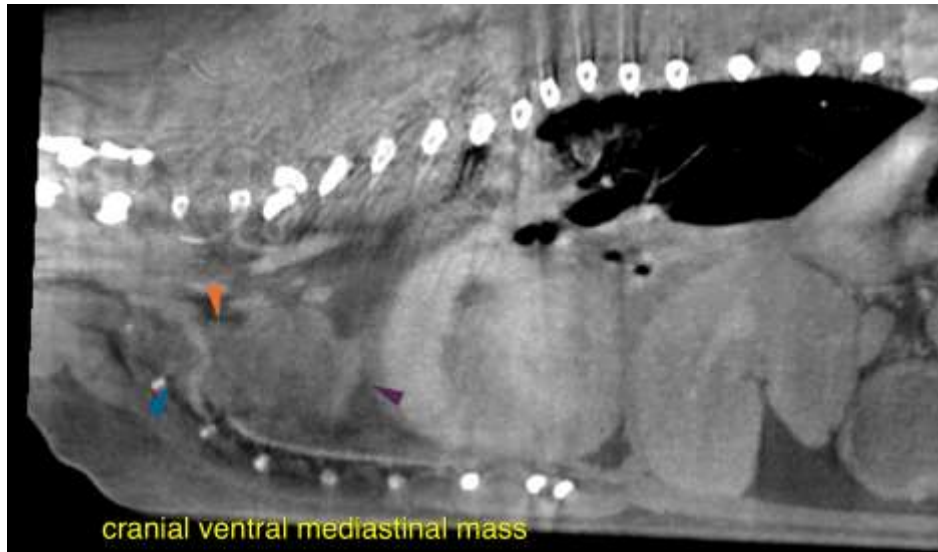
The hepatic nodules may represent benign nodular hyperplasia, regenerative nodules, or metastatic disease.

SEX

FS

AGE

10 Years



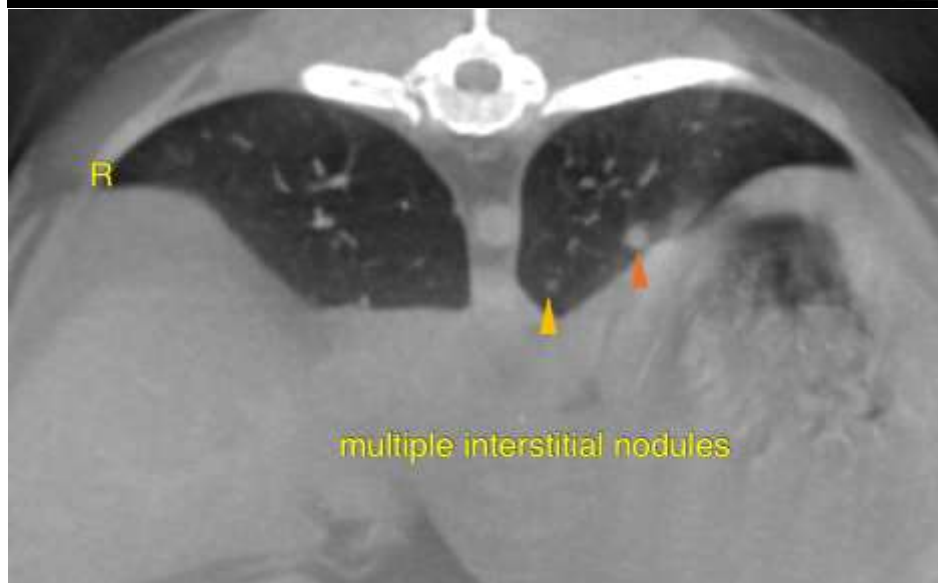
cranial ventral mediastinal mass

INTERPRETED BY

Nele Eley, DVM
Dr. med. Vet. DipECVDI

HOSPITAL NAME

Mountain West
Veterinary Hospital



multiple interstitial nodules

REFERRING VET

Andrew Burton

INVOICE

49352

DATE

1-5-22



PATIENT

Penny Ivory

The information and recommendations provided are based on the images presented by the referring veterinarian. No evaluation can be communicated regarding pathology that was not visible in the image/video clips provided.

SPECIES

Canine

Thank you for this referral. If the clinical or image interpretation does not parallel your findings or if I can be of any further assistance please contact me.

BREED

Boston Terrier

Nele Eley, DVM, Dr. med. vet., DipECVDI
European Specialist in Veterinary Diagnostic Imaging, Cert. Radiology,
Senior lecturer University of Giessen, Germany, Veterinary Faculty, Department of Radiology
Nele.Eley@sonopath.com

SEX

FS

AGE

10 Years

INTERPRETED BY

Nele Eley, DVM
Dr. med. Vet. DipECVDI

HOSPITAL NAME

Mountain West
Veterinary Hospital

REFERRING VET

Andrew Burton

INVOICE

49352

DATE

1-5-22