



PATIENT

Turner Cobb-Hoffmann

SPECIES

Canine

BREED

Rough Collie

SEX

MN

AGE

10 Years

INTERPRETED BY

Nele Eley, DVM
Dr. med. Vet. DipECVDI

HOSPITAL NAME

Animal Health Partners

REFERRING VET

Lea Mehrkens

INVOICE

55989

DATE

1-4-23

PRESENTING CLINICAL SIGNS

mass on hip. The mass was initially noticed 2 years ago. The mass was initially part of a grapefruit but appears to have grown rapidly over the past month. Doesn't appear to be in a lot of pain, his gait has changed and he can't walk normally but it doesn't seem to be bothering him anymore (lies down on it just fine, and isn't chewing it anymore). Eating and drinking well, with no other concerns noted by O. Turner was seen by West Niagara Animal Hospital and a fine needle aspirate + incisional biopsy was performed. Cytology revealed soft tissue sarcoma, grade 1. STS diagnosed on biopsy, grade 1 Bloodwork WNL taken in Dec 2022 Fibrous sarcome on hip (CT scan potentially same day please) Turner has had a previous history of arthritis.

COMPUTED TOMOGRAPHIC STUDY OF THE THORAX & ABDOMEN

Plain studies available for review in soft tissue and lung windows.

COMPUTED TOMOGRAPHIC FINDINGS

Abdomen

The CT study reveals a multilobulated cavitating soft tissue mass lateral and dorsal to the right sciatic bone as well as proximal to the right gluteal muscles. The mass measures approximately 9 cm in width, 11 cm in length, and 8 cm in height. Multiple superficial vascular anastomoses and peripheral fat stranding with ill-defined margins are seen. There is a mass effect onto the underlying gluteal musculature with no evidence of infiltration of the muscles or bones.

Both coxofemoral joints present within age related normal limits.

The pelvic bones present within age related normal limits.

A moderate amount of mineral attenuating material is seen within the renal pelvis of both kidneys. Cystic lesions are seen within both kidneys as well.

Small calculi are seen within the urinary bladder.

The spleen, liver, gallbladder, pancreas, adrenal glands, and gastrointestinal tract, as well as abdominal lymph nodes and superficial inguinal lymph nodes present within the expected normal limits on this plain CT study.

Note soft tissue emphysema in the caudodorsal right thigh musculature likely iatrogenic due to injection.

Thorax

There is no evidence of interstitial pulmonary nodules or masses. Occasional pulmonary osteomas are seen.

The mediastinal lymph nodes present within normal limits.

COMPUTED TOMOGRAPHIC DIAGNOSIS

- Large soft tissue mass proximal to the right hip meeting neoplastic criteria.



PATIENT

Turner Cobb-Hoffmann

- No evidence of metastatic disease to the regional lymph nodes or lung.
- Bilateral hypercalcemic nephropathy and renal cysts.
- Urinary bladder microlithiasis.

INTERPRETATION OF THE FINDINGS & FURTHER RECOMMENDATIONS

SPECIES

Canine

The CT study reveals a large cavitating ill-defined soft tissue mass in the subcutaneous soft tissues proximal to the right hip. Soft tissue neoplasia such as soft tissue sarcoma is a primary differential diagnosis. The findings are not compatible with organizing hematoma, abscess, or granuloma. Lesion margins are ill-defined which suggests malignancy. The underlying musculature and bones however present within normal limits and with no evidence of tissue infiltration at this point.

BREED

Rough Collie

SEX

MN

AGE

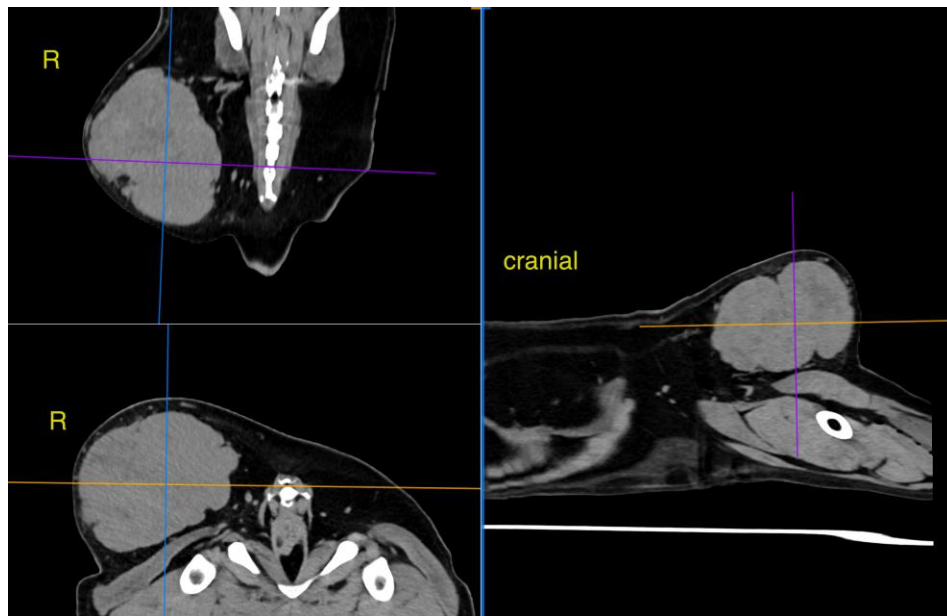
10 Years

INTERPRETED BY

Nele Eley, DVM
Dr. med. Vet. DipECVDI

HOSPITAL NAME

Animal Health Partners



REFERRING VET

Lea Mehrkens

The information and recommendations provided are based on the images presented by the referring veterinarian/sonographer. No evaluation can be communicated regarding pathology that was not visible in the image/video clips provided.

Thank you for this referral. If the clinical or image interpretation does not parallel your findings or if I can be of any further assistance please contact me.

INVOICE

55989

Nele Eley, DVM, Dr. med. vet., DipECVDI
European Specialist in Veterinary Diagnostic Imaging, Cert. Radiology,
Senior lecturer University of Giessen, Germany, Veterinary Faculty, Department of Radiology
Nele.Eley@sonopath.com

DATE

1-4-23