

**PATIENT**

Sparky Hoats

**PRESENTING CLINICAL SIGNS**

Presented for difficulty breathing/retching/stridor after being boarded for 7 days. Normal laryngeal function on sedated exam.  
Abnormal PE/Chem/CBC/UA Results: Normal

**SPECIES**

Canine

**COMPUTED TOMOGRAPHIC STUDY OF THE HEAD & NECK**

Plain and post contrast studies available for review.

**BREED**

Boston Terrier

**COMPUTED TOMOGRAPHIC FINDINGS**

The patient is a brachycephalic dog with dome shaped calvarium, shortened facial bones, and reduced number and folding of the nasal conchae.

**SEX**

MN

Aberrant retrograde growth of the turbinates is seen in the left nasal cavity.

**AGE**

7

The soft palate is thick.

The nasopharyngeal lumen is collapsed.

Mild generalized thickening of the laryngeal soft tissues is seen. The air is mostly displaced from the laryngeal ventricles.

Both tonsils are enlarged and everted.

There is mild generalized tracheal hypoplasia.

The conformation of both external auditory meatuses and tympanic bullae is thin and small.

The triadans 108, 109, 208, and 209 present moderate periodontitis.

**INTERPRETED BY**

Nele Eley, DVM  
Dr. med. Vet. DipECVDI

**COMPUTED TOMOGRAPHIC DIAGNOSIS**

- Brachycephalic upper airway stenosis with aberrant turbinates.
- Nasopharyngeal collapse.
- Thick soft palate.
- Soft tissue swelling of the larynx.
- Tracheal hypoplasia.
- Tonsillitis.
- Moderate periodontitis triadans 108, 109, 208, and 209.

**HOSPITAL NAME**

Northeast Veterinary  
Referral Hospital

**REFERRING VET**

Dr. Runde

**INVOICE**

49287

**INTERPRETATION OF THE FINDINGS & FURTHER RECOMMENDATIONS**

Significant and complex brachycephalic upper airway stenosis is seen which may explain the clinical signs. However, concurrent laryngitis, tracheitis, pharyngitis, and tonsillitis may contribute to the clinical signs as well. Correlate with the endoscopic evaluation of the larynx and soft palate as the assessment of the length of the palate as well as the upper airway dynamics is limited with CT.

**DATE**

1-4-22



**PATIENT**

Sparky Hoats

**SPECIES**

Canine

**BREED**

Boston Terrier

**SEX**

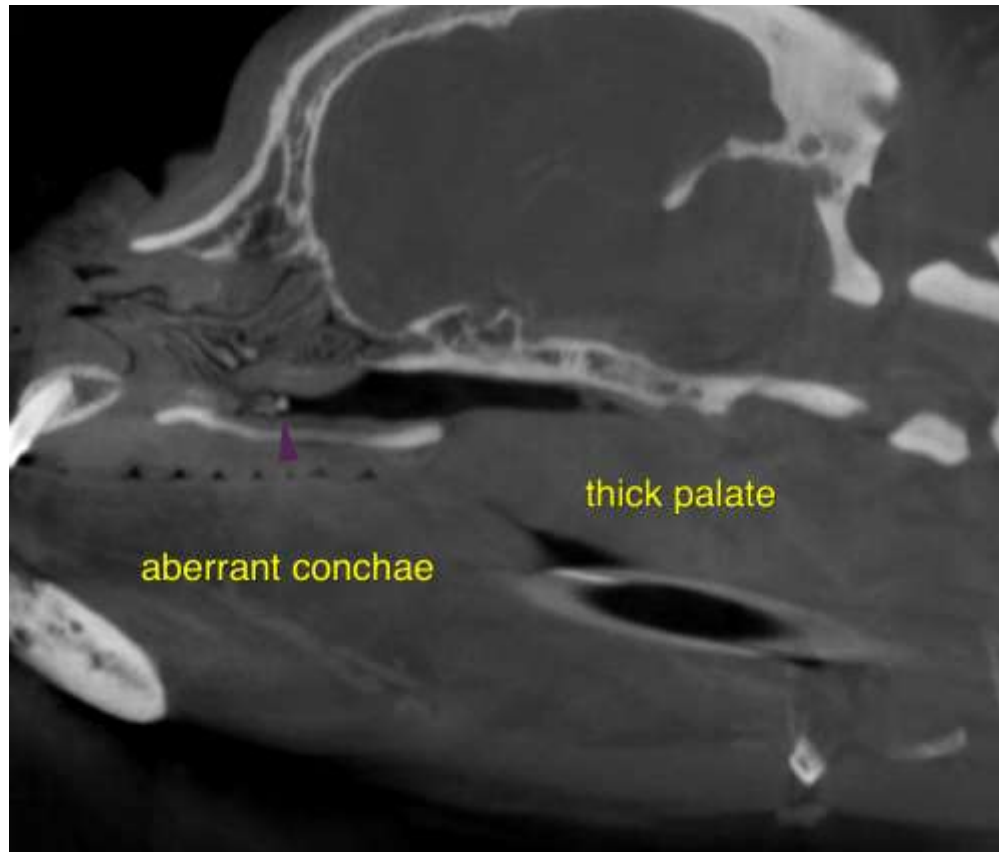
MN

**AGE**

7

**INTERPRETED BY**

Nele Eley, DVM  
Dr. med. Vet. DipECVDI



**HOSPITAL NAME**

Northeast Veterinary  
Referral Hospital

**REFERRING VET**

Dr. Runde

**INVOICE**

49287

**DATE**

1-4-22

The information and recommendations provided are based on the images presented by the referring veterinarian. No evaluation can be communicated regarding pathology that was not visible in the image/video clips provided.

Thank you for this referral. If the clinical or image interpretation does not parallel your findings or if I can be of any further assistance please contact me.

**Nele Eley**, DVM, Dr. med. vet., DipECVDI  
European Specialist in Veterinary Diagnostic Imaging, Cert. Radiology,  
Senior lecturer University of Giessen, Germany, Veterinary Faculty, Department of Radiology  
Nele.Eley@sonopath.com