



PATIENT

Bella Rosa Chrystall

PRESENTING CLINICAL SIGNS

Ran down stairs in Nov, 2022. Came up lame afterwards. No yelping but limping since then and obvious muscle waisting left rear leg
Abnormal PE/Chem/CBC/UA Results: Positive Cranial drawer, CTT, medial buttress left rear leg. Unstable stifle

SPECIES

Canine

ULTRASONOGRAPHIC FINDINGS

Left Stifle

A large amount of effusion is seen in the supra- and infra-patellar recesses of the left stifle joint. The visible joint cartilage presents increased echogenicity, increased thickness, and surface irregularity. A large amount of periarticular osteophytes is present. Capsular fibrosis and synovial proliferations are seen. The infrapatellar fat pad presents moderate heterogeneity.

BREED

Cane Corso Mastiff

SEX

Female Intact

The cranial cruciate ligament presents as a short echogenic stump surrounded by an anechoic halo at the intercondylar eminence of the tibia.

AGE

3 Years, 9 Months

The cranial and caudal horn of the medial meniscus appear to be ill-defined. The caudal horn is indistinctly seen and appears to be partially in situ only. Surface irregularity is noted and there is a large amount of synovial proliferations in the medial joint compartment.

Mild surface irregularity and mild internal heterogeneity of the lateral meniscus are seen. The lateral meniscal tissue however appears to be in situ.

INTERPRETED BY

Nele Eley, DVM
Dr. med. Vet. DipECVDI

ULTRASONOGRAPHIC DIAGNOSIS

- Severe chronic osteoarthritis.
- Full cranial cruciate ligament rupture
- Suspect medial meniscal injury.

HOSPITAL NAME

Westview Veterinary
Hospital

INTERPRETATION OF THE FINDINGS & FURTHER RECOMMENDATIONS

The ultrasonographic findings support the presence of full rupture of the cranial cruciate ligament and a medial meniscal tear. Severe concurrent osteoarthritic changes are seen. Surgical intervention is recommended in order to address the biomechanical instability and should include arthrotomy or arthroscopy in order to further evaluate and treat the presumed meniscal injury.

REFERRING VET

Dr. Brian Barnes

INVOICE

56482

DATE

1-31-23



PATIENT

Bella Rosa Chrystall

SPECIES

Canine

BREED

Cane Corso Mastiff

SEX

Female Intact

AGE

3 Years, 9 Months

INTERPRETED BY

Nele Eley, DVM
Dr. med. Vet. DipECVDI

HOSPITAL NAME

Westview Veterinary
Hospital

REFERRING VET

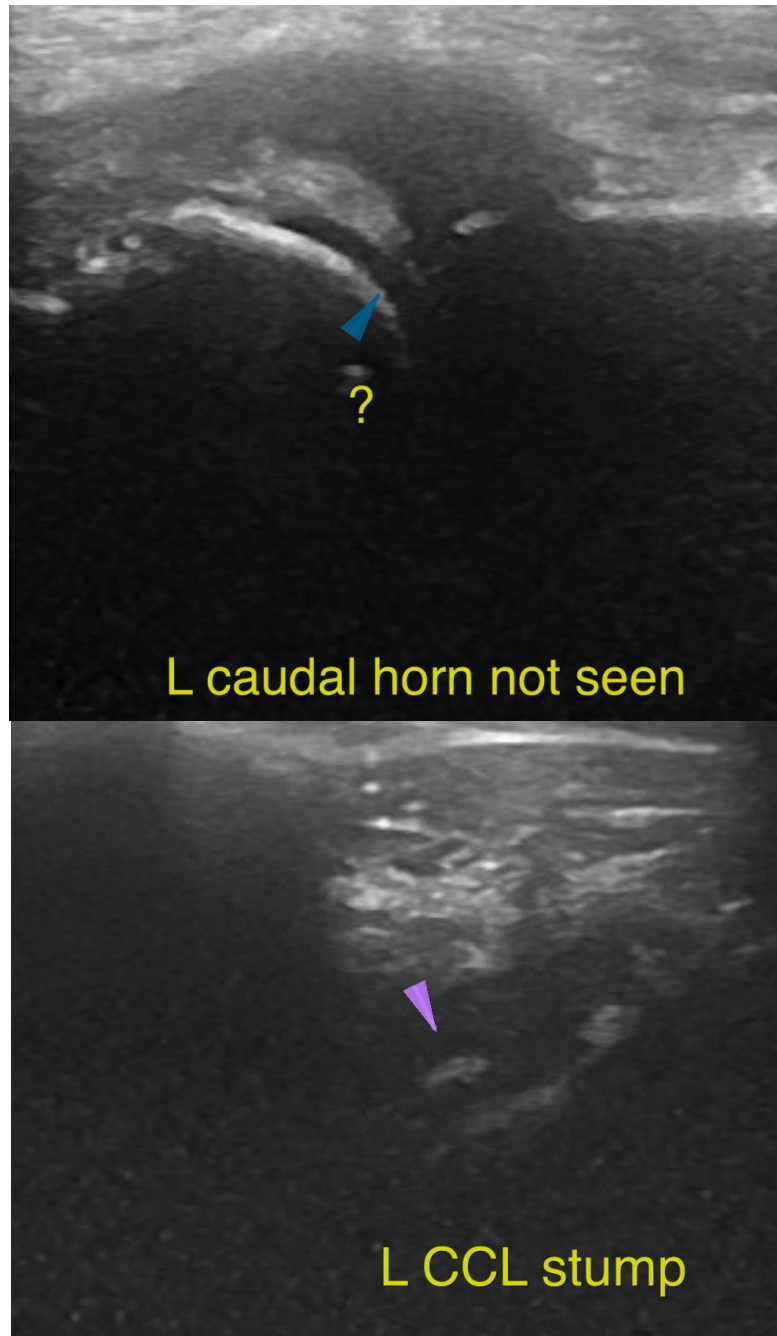
Dr. Brian Barnes

INVOICE

56482

DATE

1-31-23





PATIENT

Bella Rosa Chrystall

The information and recommendations provided are based on the images presented by the referring veterinarian/sonographer. No evaluation can be communicated regarding pathology that was not visible in the image/video clips provided.

Thank you for this referral. If the clinical or image interpretation does not parallel your findings or if I can be of any further assistance please contact me.

SPECIES

Canine

Nele Eley, DVM, Dr. med. vet., DipECVDI
European Specialist in Veterinary Diagnostic Imaging, Cert. Radiology,
Senior lecturer University of Giessen, Germany, Veterinary Faculty, Department of Radiology
Nele.Eley@sonopath.com

BREED

Cane Corso Mastiff

SEX

Female Intact

AGE

3 Years, 9 Months

INTERPRETED BY

Nele Eley, DVM
Dr. med. Vet. DipECVDI

HOSPITAL NAME

Westview Veterinary
Hospital

REFERRING VET

Dr. Brian Barnes

INVOICE

56482

DATE

1-31-23