



PATIENT

Keeva Stellabot

SPECIES

Canine

BREED

Cairn Terrier Mix

SEX

Female Spayed

AGE

10.3

INTERPRETED BY

Nele Eley, DVM
Dr. med. Vet. DipECVDI

HOSPITAL NAME

Boca Park Animal
Hospital

REFERRING VET

Tifanie Silver

INVOICE

49962

DATE

1-31-22

PRESENTING CLINICAL SIGNS

Hyperadrenocorticism Not eating Difficulty walking Lethargic appears uncomfortable
Abnormal PE/Chem/CBC/UA Results: Cushing's disease managed w/ trilostane Suspected
Addisonian crisis (iatrogenic) Elevated kidney values, including PHOS and K+ Mild to moderate
abdominal palpation Mild ataxia of the hindlimbs, CPs appropriate Moderate tension on
palpation of caudal thorax and cranial lumbar spine

RADIOGRAPHIC STUDY OF THE ABDOMEN

Right/left lateral and ventrodorsal views totaling 3 images available for review.

RADIOGRAPHIC FINDINGS

The patient is obese.

Number, alignment, and anatomy of the lumbar vertebrae present within normal limits. Moderate
T4/5 and T5/6 spondyloses are seen.

The ventral abdominal wall is pendulous.

There appears to be reduced serosal detail in the cranial abdomen caudal of the stomach.

Moderate generalized enlargement of the liver with rounded lobar margins is noted.

The gallbladder appears to be enlarged.

RADIOGRAPHIC DIAGNOSIS

- Hepatomegaly.
- Presumably distended gallbladder.
- Reduced serosal detail caudal of the stomach.
- Radiographically normal lumbar spine.

INTERPRETATION OF THE FINDINGS & FURTHER RECOMMENDATIONS

The radiographic changes of the liver are compatible with endocrine hepatopathy such as steroid
induced. Hepatitis and other cannot be ruled out entirely as a differential diagnosis; however,
appear unlikely in light of the patient's history.

The possibility of cranial abdominal peritonitis / pancreatopathy should be considered. Correlate
with the laboratory values and consider abdominal ultrasound for further definition.



PATIENT

Keeva Stellabot

SPECIES

Canine

BREED

Cairn Terrier Mix

SEX

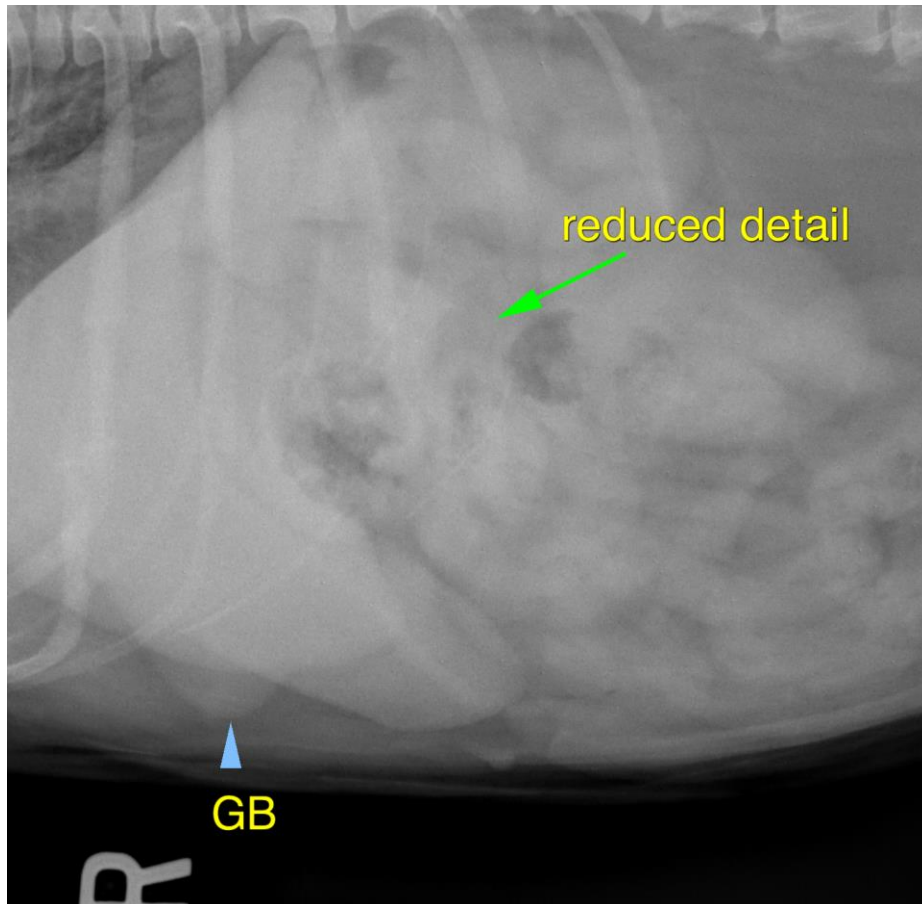
Female Spayed

AGE

10.3

INTERPRETED BY

Nele Eley, DVM
Dr. med. Vet. DipECVDI



HOSPITAL NAME

Boca Park Animal
Hospital

REFERRING VET

Tifanie Silver

INVOICE

49962

DATE

1-31-22

The information and recommendations provided are based on the images presented by the referring veterinarian/sonographer. No evaluation can be communicated regarding pathology that was not visible in the image/video clips provided.

Thank you for this referral. If the clinical or image interpretation does not parallel your findings or if I can be of any further assistance please contact me.

Nele Eley, DVM, Dr. med. vet., DipECVDI
European Specialist in Veterinary Diagnostic Imaging, Cert. Radiology,
Senior lecturer University of Giessen, Germany, Veterinary Faculty, Department of Radiology
Nele.Eley@sonopath.com