



PATIENT

Guinness Tinsley

SPECIES

Canine

BREED

Mini Australian
Shepherd

SEX

Neutered Male

AGE

6 Years

INTERPRETED BY

Nele Eley, DVM
Dr. med. Vet. DipECVDI

HOSPITAL NAME

Q Street Animal
Hospital

REFERRING VET

Bretschneider

INVOICE

49978

DATE

1-31-22

PRESENTING CLINICAL SIGNS

in last few weeks more lethargic, vomits a couple times per week. not coughing. But has substantial heart murmur - grade 4 systolic. Has been on Atenolol 50 mg 1/8 tab by mouth once per day ongoing for years. Is cryptorchid, bilateral. have not done surgery due to risks with heart condition

Abnormal PE/Chem/CBC/UA Results: pending

RADIOGRAPHIC STUDY OF THE THORAX

Right/left lateral and ventrodorsal views of the thorax and lateral and ventrodorsal views of the abdomen totaling 5 images available for review.

Thoracic read requested.

RADIOGRAPHIC FINDINGS

Severe generalized cardiomegaly is seen with a vertebral heart score of 13.2. There is no evidence of a vascular pattern or cardiogenic pulmonary edema. No significant bronchial splitting is seen, however, the long axis of the heart is enlarged causing tracheal elevation and rounding of the right ventricle is seen. On the left lateral view, the cardiac silhouette is globoid in appearance.

Dilation of the caudal vena cava and hepatomegaly appear to be present.

RADIOGRAPHIC DIAGNOSIS

- Severe cardiomegaly with presumed right and potential for left heart involvement and suspect right sided congestive heart failure.

INTERPRETATION OF THE FINDINGS & FURTHER RECOMMENDATIONS

The radiographic findings suggest predominance of right heart enlargement with emerging right sided congestive heart failure with dilation of the caudal vena cava and hepatomegaly.

Differential diagnosis includes congenital conditions such as tricuspid valve dysplasia, acquired tricuspid insufficiency, pericardial effusion, and other. Further definition by means of an echocardiogram is strongly recommended.



PATIENT

Guinness Tinsley

SPECIES

Canine

BREED

Mini Australian
Shepherd

SEX

Neutered Male

AGE

6 Years

INTERPRETED BY

Nele Eley, DVM
Dr. med. Vet. DipECVDI

HOSPITAL NAME

Q Street Animal
Hospital

REFERRING VET

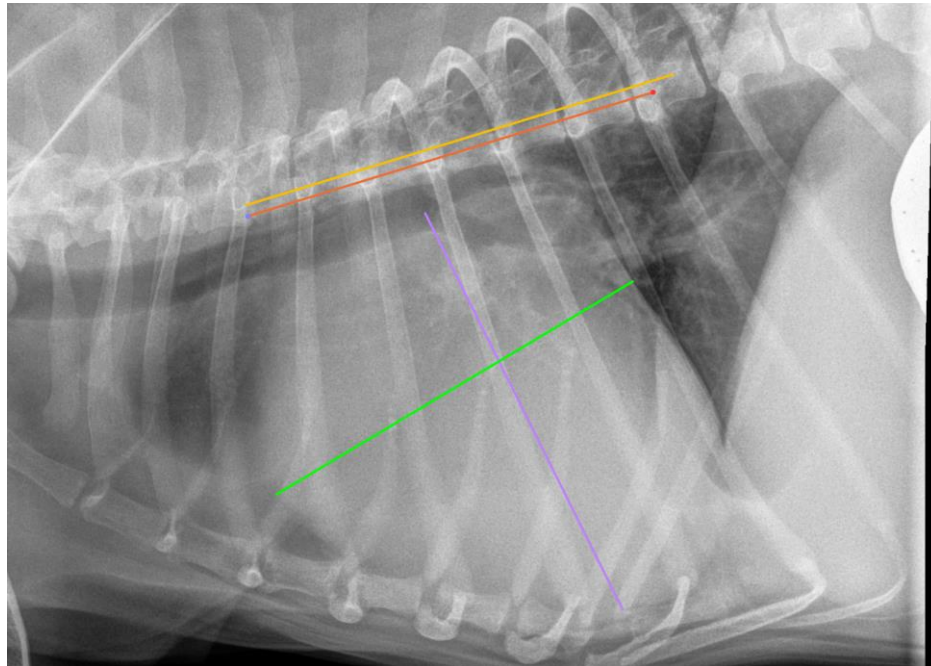
Bretschneider

INVOICE

49978

DATE

1-31-22



The information and recommendations provided are based on the images presented by the referring veterinarian/sonographer. No evaluation can be communicated regarding pathology that was not visible in the image/video clips provided.

Thank you for this referral. If the clinical or image interpretation does not parallel your findings or if I can be of any further assistance please contact me.

Nele Eley, DVM, Dr. med. vet., DipECVDI
European Specialist in Veterinary Diagnostic Imaging, Cert. Radiology,
Senior lecturer University of Giessen, Germany, Veterinary Faculty, Department of Radiology
Nele.Eley@sonopath.com