



## PATIENT PRESENTING CLINICAL SIGNS

- Murph Campbell
- Chronic louder upper airway noises in a brachycephalic dog, with episodes of waking from sleep wet with saliva, hard swallowing, licking, and possible brief arousals that could resemble apnea. Sneezing occurs every morning in clusters of 3-4 and intermittently throughout the day, worsened by exercise and excitement. Owner has attempted to identify a side predominance with sneezing but is uncertain. There is occasional malodor not clearly dental in origin. No observed facial pain or asymmetry. No reported changes in appetite or weight loss.

## SPECIES

Canine

## BREED COMPUTED TOMOGRAPHIC STUDY OF THE HEAD

Cane Corso Plain and post contrast studies are available for review.

## COMPUTED TOMOGRAPHIC FINDINGS

### SEX

The patient has a brachycephalic head conformation with shortened facial bones.

### MN

Bilateral nares stenosis grade 2 -3 likely due to lateral alar cartilage distortion and narrowing of the nares is seen. Reduced number and folding of nasal turbinates are present. Retrograde elongation of the turbinates more pronounced on the right side is seen.

### AGE

5yr

The soft palate is thick with 20 mm. No overt elongation is noted under intubation.

## INTERPRETED BY

Nele Eley (Ondreka),  
DVM Dr. med. vet.,  
DipECVDI

The nasopharyngeal lumen appears collapsed; generalized thickening of the laryngeal soft tissues appears to be present with no discrete mass effect.

No evidence of active rhinitis or sinusitis is seen. No focal destructive lesions or significant mucosal swelling is identified.

There is no evidence of clinically relevant dental disease.

## HOSPITAL NAME

Southern Oregon  
Veterinary Specialty  
Center

Normal regional lymph nodes are noted.

A left-sided 15 mm x 5 mm sized nodule is seen lateral and cranial to the left thyroid lobe, likely representing ectopic thyroid/ parathyroid tissue or supernumerary lymph node.

## REFERRING VET

Dr. Rory Applegate

## COMPUTED TOMOGRAPHIC DIAGNOSIS

- Findings are consistent with brachycephalic obstructive airway syndrome including nares stenosis, turbinate abnormalities, thickened soft palate and nasopharyngeal lumen collapse
- No evidence of active rhinitis, sinusitis or dental disease to explain the sneezing and nasal noises is noted
- Small left-sided thyroid / parathyroid or lymph node nodule is likely incidental-correlation with clinical chemistry or ultrasound can be considered if indicated

## INVOICE

23732

## DATE

01/30/2026

## INTERPRETATION OF FINDINGS & FURTHER RECOMMENDATIONS



**PATIENT**

Murph Campbell

Clinical management for brachycephalic obstructive airway syndrome, dynamic assessment of the upper airways to rule out elongated soft palate, laryngeal malfunction, pharyngeal collapse, laryngeal malfunction or other is recommended to complement the CT examination. Surgical consultation may be considered if symptomatic severity increases.

**SPECIES**

Canine

The incidental thyroid/ parathyroid/ lymph node nodule may warrant laboratory characterization and sampling if clinically indicated.

**BREED**

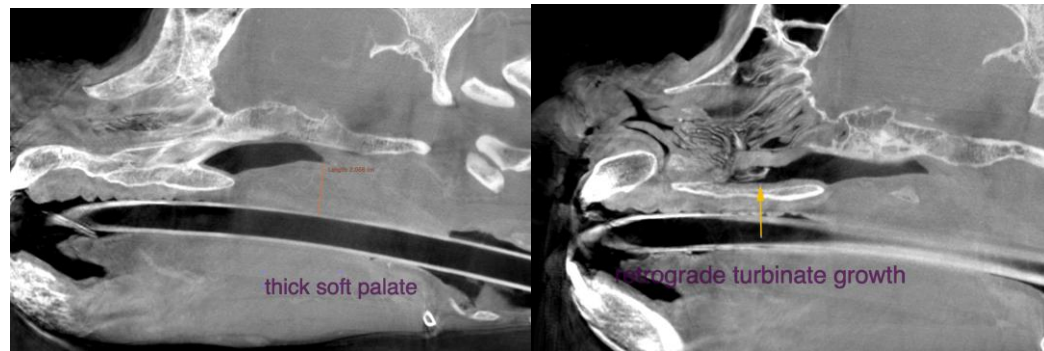
Cane Corso

**SEX**

MN

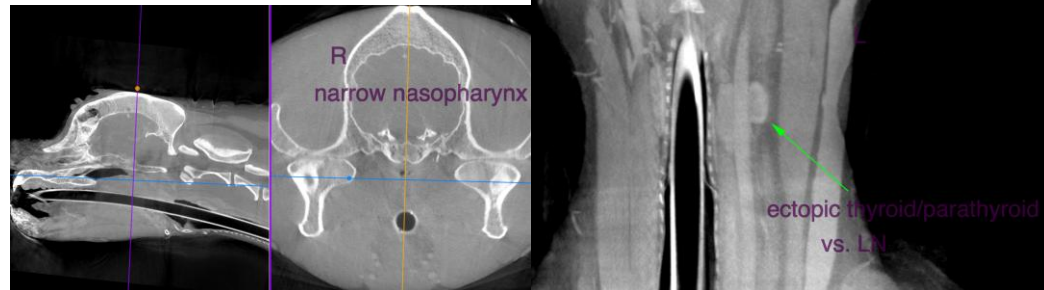**AGE**

5yr



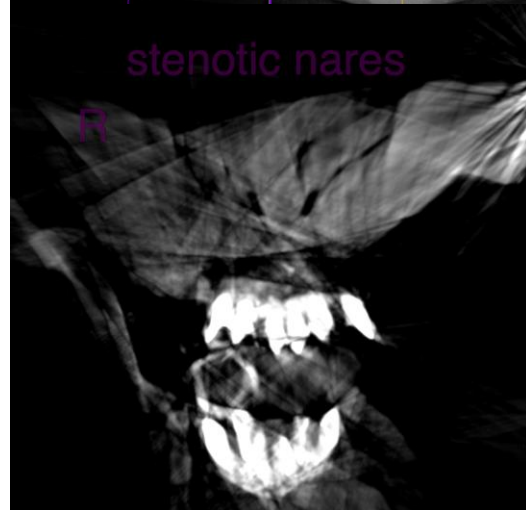
**INTERPRETED BY**

Nele Eley (Ondreka),  
DVM Dr. med. vet.,  
DipECVDI



**HOSPITAL NAME**

Southern Oregon  
Veterinary Specialty  
Center



**REFERRING VET**

Dr. Rory Applegate

**INVOICE**

23732

**DATE**

01/30/2026



## PATIENT

Murph Campbell

The information and recommendations provided are based on the images presented by the referring veterinarian. No evaluation can be communicated regarding pathology that was not visible in the image/video clips provided.

## SPECIES

Canine

Thank you for this referral. If the clinical or image interpretation does not parallel your findings or if I can be of any further assistance please contact me.

## BREED

Cane Corso

**Nele Eley (Ondreka)**, DVM, Dr. med. vet., DipECVDI  
European Specialist in Veterinary Diagnostic Imaging, Cert. Radiology,  
Senior lecturer University of Giessen/Germany, Veterinary Faculty, Department of Radiology.  
[info@sonopath.com](mailto:info@sonopath.com)

## SEX

MN

## AGE

5yr

## INTERPRETED BY

Nele Eley (Ondreka),  
DVM Dr. med. vet.,  
DipECVDI

## HOSPITAL NAME

Southern Oregon  
Veterinary Specialty  
Center

## REFERRING VET

Dr. Rory Applegate

## INVOICE

23732

## DATE

01/30/2026