



## PATIENT PRESENTING CLINICAL SIGNS

**PATIENT** Jake Proctor  
**SPECIES** Canine  
**BREED** Border Collie

Owner reports Jake had a swelling around his face yesterday and had half of a paracetamol tablet at home and today started passing blood from his Left nostril intermittently but large volume? On the clinical exam moderate epistaxis from the L nostril, stops when calmed, BAR, teeth with tartum+++ and gingivitis present, area under the R eye swollen possibly due to the dental disease (owner reports eating less biscuits than usual), abdomen soft on palpation, temp wnl, no obvious bruising. Chat with the owner and advise diagnosis open at this stage and epistaxis can be related to dental disease vs nasal FB/polyp, etc. Given the option for admission vs start on symptomatic tx and rx tomorrow. Owner keen for admission. Went through the consent form and finances. owner happy to proceed. Bloods unremarkable PCV 45% Stable overnight, BAR, eating, passing urine but no stools, pain scoring low, intermittent epistaxis when excited but reduced volume. Plan to sedate and take X-rays and if no concerns then TGH on oral meds and book for a dental

## COMPUTED TOMOGRAPHIC STUDY OF THE HEAD

**SEX** Plain and post contrast studies are available for review.

M

## COMPUTED TOMOGRAPHIC FINDINGS

**AGE** 7yr

Regional mucosal thickening and soft tissue swelling involving the right ventral nasal concha and ventral nasal meatus is seen associated with small amounts of fluid attenuating material. No discrete mass lesion is identified. There is no evidence of aggressive bone or turbinate destruction. The nasal septum is intact. No convincing foreign material is identified. The remaining nasal passages present with normal limits.

## INTERPRETED BY

Nele Eley (Ondreka),  
DVM Dr. med. vet.,  
DipECVDI

Multifocal dental resorptive lesions most pronounced in the maxillary premolar teeth particularly 108 and 208 with additional involvement of the incisors is noted. Marked periodontal ligament space widening is associated with teeth 110, 210, 310, 410. Horizontal alveolar bone loss with superimposed multifocal vertical bone loss is seen in all quadrants consistent with chronic periodontal disease. No evidence of oral nasal fistula formation is noted.

## HOSPITAL NAME

Animal Trust  
Ellesmere

Mild lateral lymphadenomegaly of the submandibular and retropharyngeal lymph nodes likely reactive in nature is seen.

## COMPUTED TOMOGRAPHIC DIAGNOSIS

## REFERRING VET

Amber Mahon

- Right-sided nasal mucosal thickening and fluid accumulation without evidence of a mass, foreign body or aggressive osseous destruction.
- Severe chronic dental and periodontal disease including multifocal tooth resorption and advanced periodontal ligament and alveolar bone changes.
- Mild reactive regional lymphadenopathy

## INVOICE

23424

## DATE

01/03/2026

## INTERPRETATION OF FINDINGS & FURTHER RECOMMENDATIONS

The CT study reveals regional mucosal thickening in the right nasal cavity. The findings are most consistent with inflammatory or reactive rhinitis potentially with inflammatory or reactive rhinitis Organizing hematoma is a possible differential diagnosis. Neoplasia is considered unlikely based on the absence of a discrete mass or bone lysis.



## PATIENT

Jake Proctor

The CT findings do not support an aggressive nasal process or such as neoplasia or fungal disease. Dental associated inflammatory processes are noted which represent a plausible source of facial swelling and intermittent epistaxis and reactive lymphadenitis.

## SPECIES

Canine

Consider a rhinoscopy and /or biopsy for further evaluation if epistaxis persists or worsens following dental therapy.

## BREED

Border Collie

## SEX

M

## AGE

7yr

## INTERPRETED BY

Nele Eley (Ondreka),  
DVM Dr. med. vet.,  
DipECVDI

## HOSPITAL NAME

Animal Trust  
Ellesmere

## REFERRING VET

Amber Mahon

## INVOICE

23424

## DATE

01/03/2026



## PATIENT

Jake Proctor

## SPECIES

Canine

## BREED

Border Collie

## SEX

M

## AGE

7yr

## INTERPRETED BY

Nele Eley (Ondreka),  
DVM Dr. med. vet.,  
DipECVDI

## HOSPITAL NAME

Animal Trust  
Ellesmere

## REFERRING VET

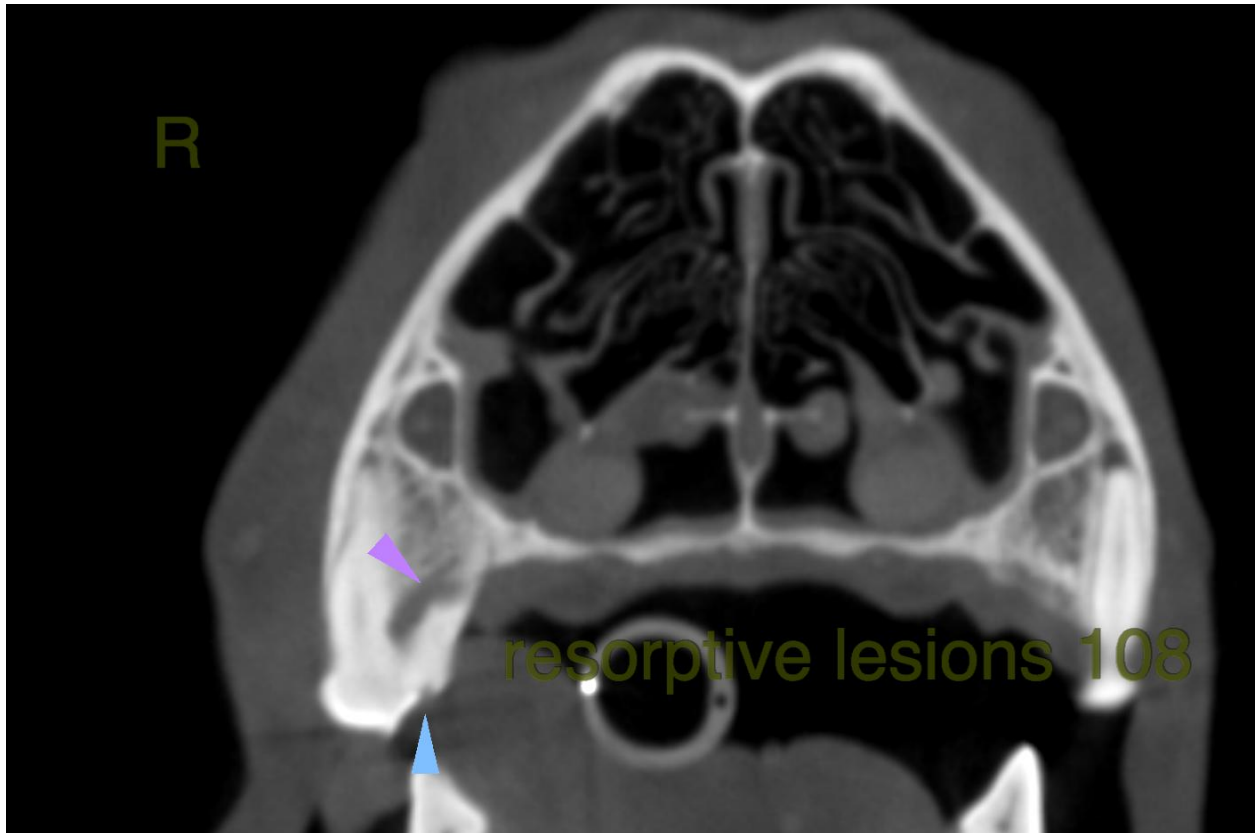Amber Mahon

## INVOICE

23424

## DATE

01/03/2026





## PATIENT

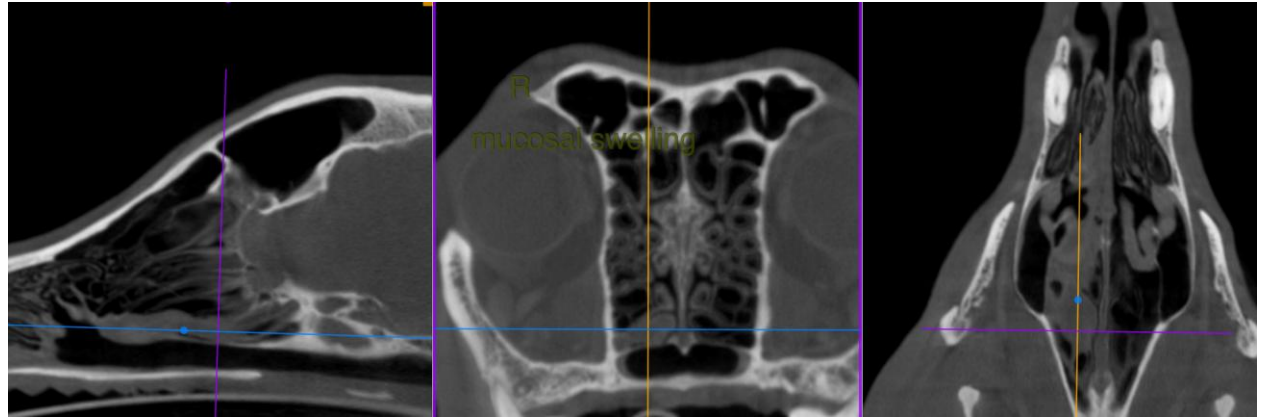
Jake Proctor

## SPECIES

Canine

## BREED

Border Collie



## SEX

M

## AGE

7yr

## INTERPRETED BY

Nele Eley (Ondreka),  
DVM Dr. med. vet.,  
DipECVDI

## HOSPITAL NAME

Animal Trust  
Ellesmere

## REFERRING VET

Amber Mahon

## INVOICE

23424

## DATE

01/03/2026



## PATIENT

Jake Proctor

## SPECIES

Canine

## BREED

Border Collie

## SEX

M

## AGE

7yr

## INTERPRETED BY

Nele Eley (Ondreka),  
DVM Dr. med. vet.,  
DipECVDI

## HOSPITAL NAME

Animal Trust  
Ellesmere

## REFERRING VET

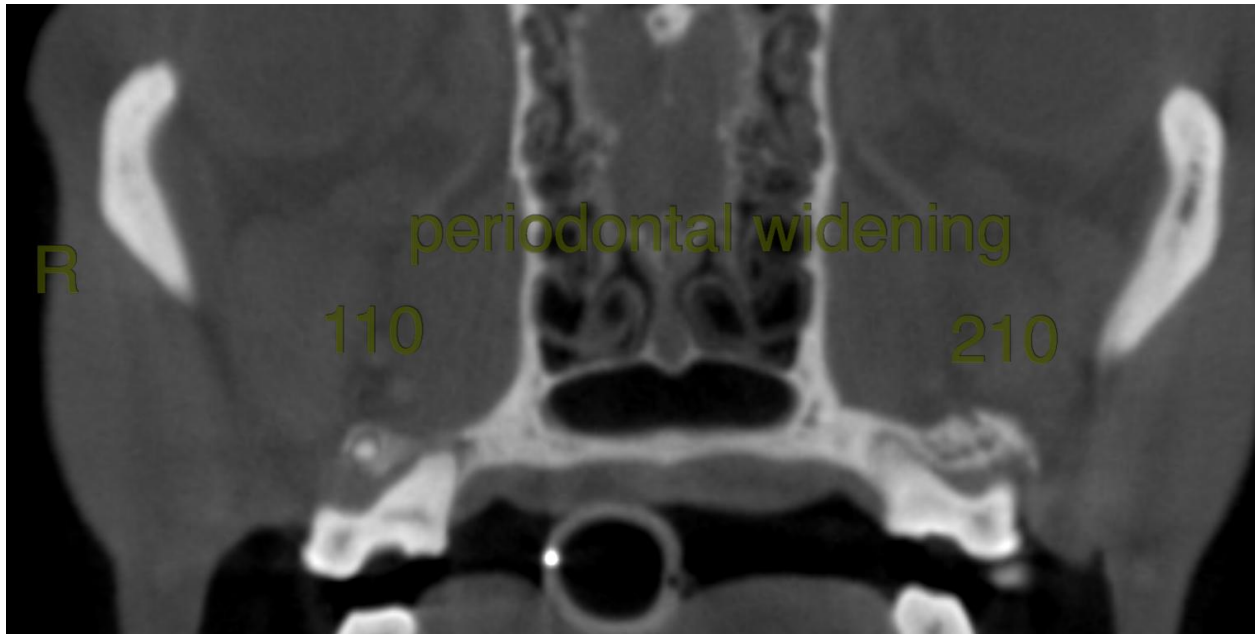
Amber Mahon

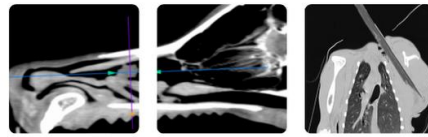
## INVOICE

23424

## DATE

01/03/2026





## PATIENT

Jake Proctor

The information and recommendations provided are based on the images presented by the referring veterinarian. No evaluation can be communicated regarding pathology that was not visible in the image/video clips provided.

## SPECIES

Canine

Thank you for this referral. If the clinical or image interpretation does not parallel your findings or if I can be of any further assistance please contact me.

## BREED

Border Collie

**Nele Eley (Ondreka)**, DVM, Dr. med. vet., DipECVDI  
European Specialist in Veterinary Diagnostic Imaging, Cert. Radiology,  
Senior lecturer University of Giessen/Germany, Veterinary Faculty, Department of Radiology.  
[info@sonopath.com](mailto:info@sonopath.com)

## SEX

M

## AGE

7yr

## INTERPRETED BY

Nele Eley (Ondreka),  
DVM Dr. med. vet.,  
DipECVDI

## HOSPITAL NAME

Animal Trust  
Ellesmere

## REFERRING VET

Amber Mahon

## INVOICE

23424

## DATE

01/03/2026