



**PATIENT**

Tyson Maujir

**PRESENTING CLINICAL SIGNS**

sudden onset of right back leg lameness during his daily routine walking, EDUD still normal no VDCA

**SPECIES**

Canine

Abnormal PE/Chem/CBC/UA Results: BCS: 6.5/9, RHL lameness, positive cranial drawer test and Tibial Thrust, not ambulating fully, mild clicking sound over the right stifle, left stifle also has moderate clicking sound, Bloodwork unremarkable including 4DX, sent home with NSAID and chondroprotective supplements.

**BREED**

Boxer Mix

**RADIOGRAPHIC STUDY OF THE RIGHT STIFLE, PELVIS, & LUMBAR SPINE**

Mediolateral view of the right stifle, ventrodorsal view of the pelvis, and lateral views of the lumbar spine totaling 4 images available for review.

**SEX**

Male Neutered

**RADIOGRAPHIC FINDINGS**

**Right Stifle**

Moderate articular swelling of the right stifle joint is seen. There is a moderate amount of periarticular osteophytes in the distal pole of the patella, femoral trochlea, fabellae, and tibial plateau margins. Moderate cranial thrust of the tibia is seen.

**AGE**

9 Years

The left stifle joint presents severe osteoarthritic changes on the craniocaudal view.

**INTERPRETED BY**

Nele Eley, DVM  
Dr. med. Vet. DipECVDF

**Pelvis**

Both coxofemoral joints present evidence of moderate dysplasia and moderate bilateral secondary osteoarthritic changes and mild subluxation.

The muscle volume of the left hind limb appears to be reduced.

**HOSPITAL NAME**

Lakeshore Woods  
Animal Hospital

**Lumbar Spine**

The patient is obese.

Severe T12/13 and mild L1/2 spondylosis deformans is seen.

**REFERRING VET**

Dr. Sam Masoud

There is moderate degenerative lumbosacral stenosis with vertebral end plate sclerosis, narrow intervertebral disc space, and moderate spondylosis deformans.

Varying degrees of spondyloses are seen throughout the imaged thoracic spine.

**INVOICE**

55962

- Moderate right stifle osteoarthritis with radiographic evidence of cruciate ligament failure.
- Disuse atrophy of the left hind limb musculature.
- Severe osteoarthritis of the left stifle joint.
- Moderate bilateral canine hip dysplasia with moderate secondary coxofemoral joint osteoarthritis.
- Degenerative lumbosacral stenosis.

**DATE**

1-3-23



**PATIENT**

Tyson Maujir

- Multiple spondyloses.

**INTERPRETATION OF THE FINDINGS & FURTHER RECOMMENDATIONS**

The radiographic study confirms the suspicion of cruciate ligament injury in the right stifle. Concurrent meniscopathy cannot be ruled out. There are moderate osteoarthritic signs of the right stifle.

**SPECIES**

Canine

The patient appears to disuse the left hind limb chronically as indicated per the muscle atrophy. Severe osteoarthritis of the left stifle joint is noted as well and may be due to primary degenerative joint disease, cruciate ligament injury, and/or meniscopathy as well as post-traumatic or other arthritis. Clinical correlation required.

**BREED**

Boxer Mix

Note the presence of bilateral coxofemoral joint osteoarthritis secondary to canine hip dysplasia as well as radiographic signs of degenerative lumbosacral stenosis.

**SEX**

Male Neutered

**AGE**

9 Years

**INTERPRETED BY**

Nele Eley, DVM  
Dr. med. Vet. DipECVDI

**HOSPITAL NAME**

Lakeshore Woods  
Animal Hospital

**REFERRING VET**

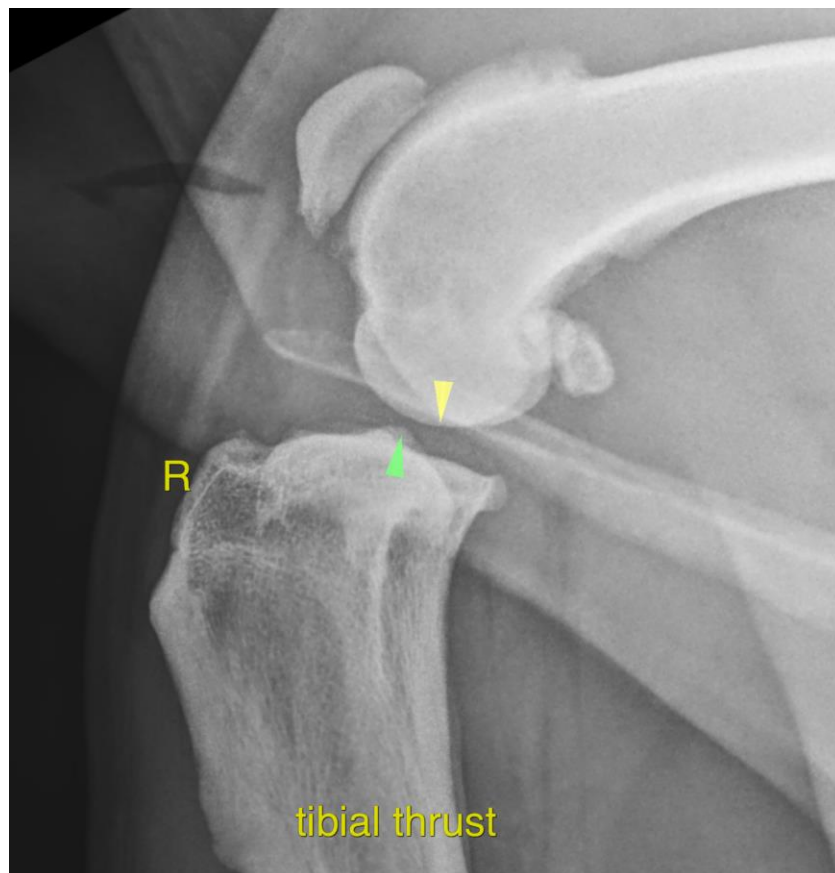
Dr. Sam Masoud

**INVOICE**

55962

**DATE**

1-3-23





**PATIENT**

Tyson Maujir

The information and recommendations provided are based on the images presented by the referring veterinarian/sonographer. No evaluation can be communicated regarding pathology that was not visible in the image/video clips provided.

**SPECIES**

Canine

Thank you for this referral. If the clinical or image interpretation does not parallel your findings or if I can be of any further assistance please contact me.

**BREED**

Boxer Mix

**Nele Eley**, DVM, Dr. med. vet., DipECVDI  
European Specialist in Veterinary Diagnostic Imaging, Cert. Radiology,  
Senior lecturer University of Giessen, Germany, Veterinary Faculty, Department of Radiology  
Nele.Eley@sonopath.com

**SEX**

Male Neutered

**AGE**

9 Years

**INTERPRETED BY**

Nele Eley, DVM  
Dr. med. Vet. DipECVDI

**HOSPITAL NAME**

Lakeshore Woods  
Animal Hospital

**REFERRING VET**

Dr. Sam Masoud

**INVOICE**

55962

**DATE**

1-3-23