



PATIENT

Chico Li

PRESENTING CLINICAL SIGNS

Did dental surgery on December 14 and recovered very well. Owner fed him soft food for 2 weeks after surgery. Mouth healing is great but when O started feeding dry food a couple of days ago he began choking and vomiting immediately after eating dry food.

SPECIES

Canine

RADIOGRAPHIC STUDY OF THE THORAX

Right/left lateral and ventrodorsal views of the thorax totaling 5 images available for review.

BREED

Miniature Poodle

RADIOGRAPHIC FINDINGS

Mild dorsal flattening of the cervical trachea is seen. There is no evidence of intrathoracic trachea or bronchial collapse.

SEX

Neutered Male

The vertebral heart score is 10. No specific chamber enlargement is noted. The pulmonary vasculature presents within normal limits.

AGE

15 Years

There is no evidence of abnormal mediastinal widening.

The lung presents a moderate generalized bronchointerstitial pattern which may be enhanced by the fair degree of pulmonary inflation.

Relatively far cranial excursion of the diaphragm is seen which may indicate restriction of the upper airways.

INTERPRETED BY

Nele Eley, DVM
Dr. med. Vet. DipECVDI

There is moderate gastrointestinal aerophagia.

Cranial lumbar spondylosis deformans and intervertebral disc space collapse is noted.

HOSPITAL NAME

Truscott Animal
Hospital

RADIOGRAPHIC DIAGNOSIS

- Moderate generalized bronchointerstitial lung pattern.
- Aerophagia.
- Mild cervical tracheal collapse.

REFERRING VET

Dr. Medhat Meawad

INTERPRETATION OF THE FINDINGS & FURTHER RECOMMENDATIONS

The radiographic study reveals a generalized bronchointerstitial lung pattern which may be within age related normal limits. Eosinophilic bronchopneumopathy or infectious bronchitis cannot be ruled out entirely as a differential diagnosis to correlate with the clinical findings. Further definition by means of airway endoscopy with airway sampling could be pursued in case of pertinent clinical signs.

INVOICE

55994

The radiographic findings furthermore suggests potential for dynamic tracheal disease.

The aerophagia can be due to pain, stress, or dyspnea.

DATE

1-3-23



PATIENT

Chico Li

SPECIES

Canine

BREED

Miniature Poodle

SEX

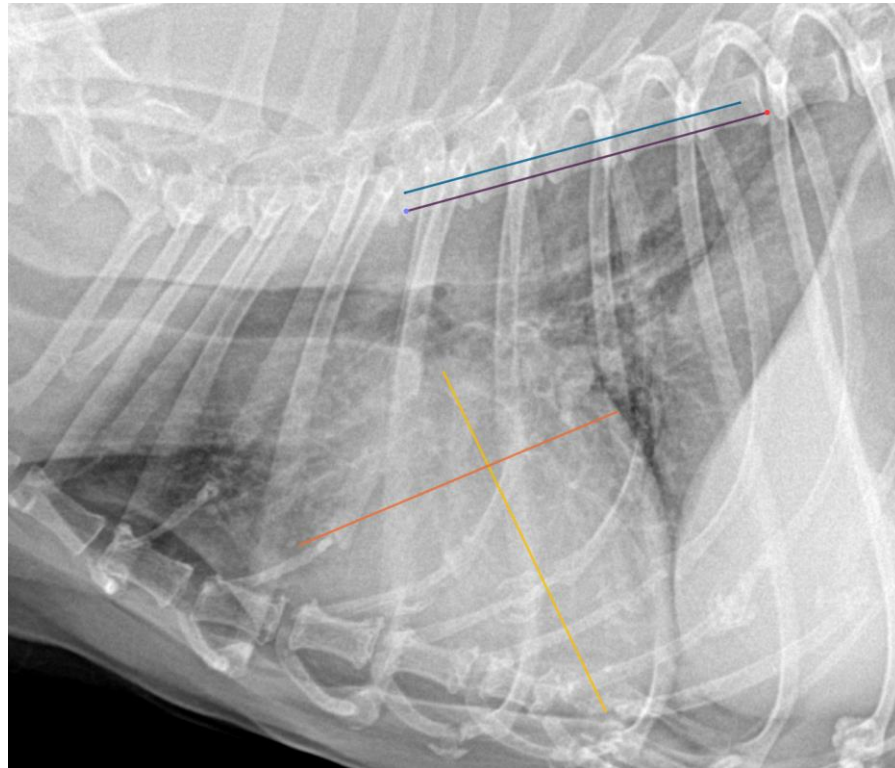
Neutered Male

AGE

15 Years

INTERPRETED BY

Nele Eley, DVM
Dr. med. Vet. DipECVDI



HOSPITAL NAME

Truscott Animal
Hospital

REFERRING VET

Dr. Medhat Meawad

INVOICE

55994

DATE

1-3-23

The information and recommendations provided are based on the images presented by the referring veterinarian/sonographer. No evaluation can be communicated regarding pathology that was not visible in the image/video clips provided.

Thank you for this referral. If the clinical or image interpretation does not parallel your findings or if I can be of any further assistance please contact me.

Nele Eley, DVM, Dr. med. vet., DipECVDI
European Specialist in Veterinary Diagnostic Imaging, Cert. Radiology,
Senior lecturer University of Giessen, Germany, Veterinary Faculty, Department of Radiology
Nele.Eley@sonopath.com