



PATIENT PRESENTING CLINICAL SIGNS

Charlie McVeay Pet given collard greens yesterday at 9pm. Vomited at 5am today, given pepto. This afternoon drank water and held down until 2pm vomited collard greens and white liquid. Abnormal PE/Chem/CBC/UA Results: CFPLI abnormal

SPECIES RADIOGRAPHIC STUDY OF THE THORAX

Canine Right/left lateral and ventrodorsal views of the thorax available for review.

BREED RADIOGRAPHIC FINDINGS

Pomeranian The patient is obese.
Bilateral elbow osteoarthritis is noted.

SEX The degree of pulmonary inflation is fair on all available images.

MN The esophagus is mildly dilated and contains a mild amount of gas.

AGE Mild ventral deviation of the precardial trachea is seen due to the esophageal dilation. There is mild redundancy of the dorsal tracheal ligament with no evidence of true collapse.

9 Years The size and shape of the cardiac silhouette present within normal limits.

INTERPRETED BY There appears to be a large amount of mediastinal fat. No mediastinal mass effect is seen.

Nele Eley, DVM
Dr. med. Vet. DipECVDI The lung and bronchial tree present within age related normal limits.

There is moderate generalized hepatomegaly.

HOSPITAL NAME Gastric aerophagia is noted.

Golden Isles Animal
Hospital

RADIOGRAPHIC DIAGNOSIS

REFERRING VET

James Hornbuckle

- Mild esophageal aerophagia versus esophageal dilation.
- Normal age related lung and bronchial tree.
- Redundancy of the dorsal tracheal ligament
- Normal radiographic presentation of the cardiovascular structures.
- Obesity
- Hepatomegaly (refer to prior report on the abdomen).

INVOICE INTERPRETATION OF THE FINDINGS & FURTHER RECOMMENDATIONS

55961 Mild dilation of the esophagus is noted and may reflect aerophagia. Esophageal dysphagia, megaesophagus (idiopathic, toxic, endocrine), and esophagitis are potential but less likely differential diagnoses.

DATE

1-2-23 The redundancy of the dorsal tracheal ligament can be an incidental finding. It can also be associated with dynamic tracheal disease. Clinical correlation required.



PATIENT

Charlie McVeay

SPECIES

Canine

BREED

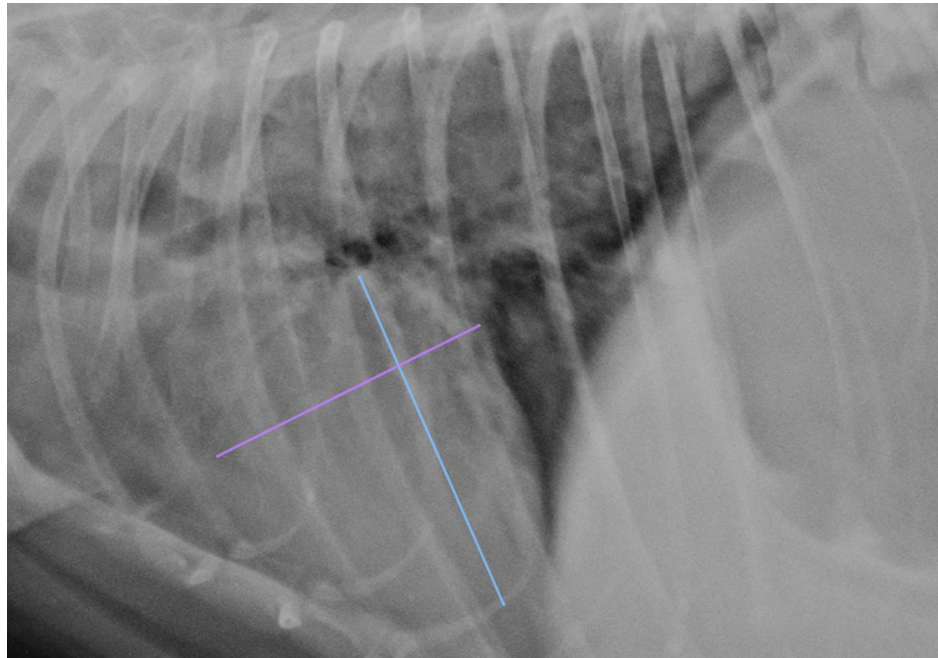
Pomeranian

SEX

MN

AGE

9 Years



INTERPRETED BY

Nele Eley, DVM
Dr. med. Vet. DipECVDI

The information and recommendations provided are based on the images presented by the referring veterinarian/sonographer. No evaluation can be communicated regarding pathology that was not visible in the image/video clips provided.

Thank you for this referral. If the clinical or image interpretation does not parallel your findings or if I can be of any further assistance please contact me.

HOSPITAL NAME

Golden Isles Animal
Hospital

Nele Eley, DVM, Dr. med. vet., DipECVDI
European Specialist in Veterinary Diagnostic Imaging, Cert. Radiology,
Senior lecturer University of Giessen, Germany, Veterinary Faculty, Department of Radiology
Nele.Eley@sonopath.com

REFERRING VET

James Hornbuckle

INVOICE

55961

DATE

1-2-23