



PATIENT

PRESENTING CLINICAL SIGNS

ROCCO FRANZESE

Rocco presented for severe cervical pain which started on Saturday Jan 1st. No trauma was reported. Owner gave 200mg of gabapentin for pain and reported the dog seemed a touch better after medications. Rocco also had 2 episodes of inappropriate urination. No BM has been recorded since Sat.

SPECIES

Canine

COMPUTED TOMOGRAPHIC STUDY OF THE SPINE

Plain study of the cervical, thoracic, and lumbar spine available for review.

BREED

French Bulldog

COMPUTED TOMOGRAPHIC FINDINGS

The craniocervical junction presents within normal limits.

SEX

Number, alignment, and anatomy of the cervical vertebrae present within normal limits.

MN

There is mineral attenuating material dorsal of the C2/3 intervertebral disc space within the ventral epidural space of the vertebral canal which appears to be part of a disc hernia. The spinal cord appears to be deviated and compressed dorsally.

AGE

4 Years

Multiple chondroid disc degeneration is seen throughout the cervical spine.

Serial congenital vertebral malformation is present within the thoracic spine at T3 representing a short vertebra; T5, T6, T7, T8, T9, T10, and T13 representing hemivertebrae.

INTERPRETED BY

Nele Eley, DVM
Dr. med. Vet. DipECVDI

Mild vertebral canal stenosis and kyphosis is seen level of T8.

L4 and L6 are hemivertebrae.

HOSPITAL NAME

Animal Surgical
Center

Moderate mid lumbar vertebral canal stenosis is seen at L4 and there is moderate lumbar/lumbosacral scoliosis.

Severe spondylosis deformans is present between the last lumbar vertebra and the sacrum with incomplete development and incomplete fusion of the ossification centers of the sacrum and moderate lumbosacral stenosis.

REFERRING VET

Twins Veterinary
Hospital

COMPUTED TOMOGRAPHIC DIAGNOSIS

- Moderate and presumably compressive disc hernia C2/3 - probably chronic.
- Multiple congenital vertebral malformation with mild mid thoracic and moderate mid lumbar vertebral canal stenosis, kyphosis, and scoliosis.
- Lumbosacral stenosis with spondylosis deformans, congenital vertebral malformation of the sacrum, and lumbosacral disc protrusion.

INVOICE

49354

INTERPRETATION OF THE FINDINGS & FURTHER RECOMMENDATIONS

DATE

1-3-22

Multiple sites of potential spinal cord or cauda equina compression are identified on this plain CT study of the spine. It is considered likely that the character of the pathologies identified is chronic which needs to be correlated with the current clinical signs. A single site of significant compression cannot be isolated and further definition by means of CT myelogram or MRI would



PATIENT

be ideal depending on the severity and development of the patient's clinical signs.

ROCCO FRANZESE

SPECIES

Canine

BREED

French Bulldog

SEX

MN

AGE

4 Years

INTERPRETED BY

Nele Eley, DVM
Dr. med. Vet. DipECVDI

HOSPITAL NAME

Animal Surgical
Center

REFERRING VET

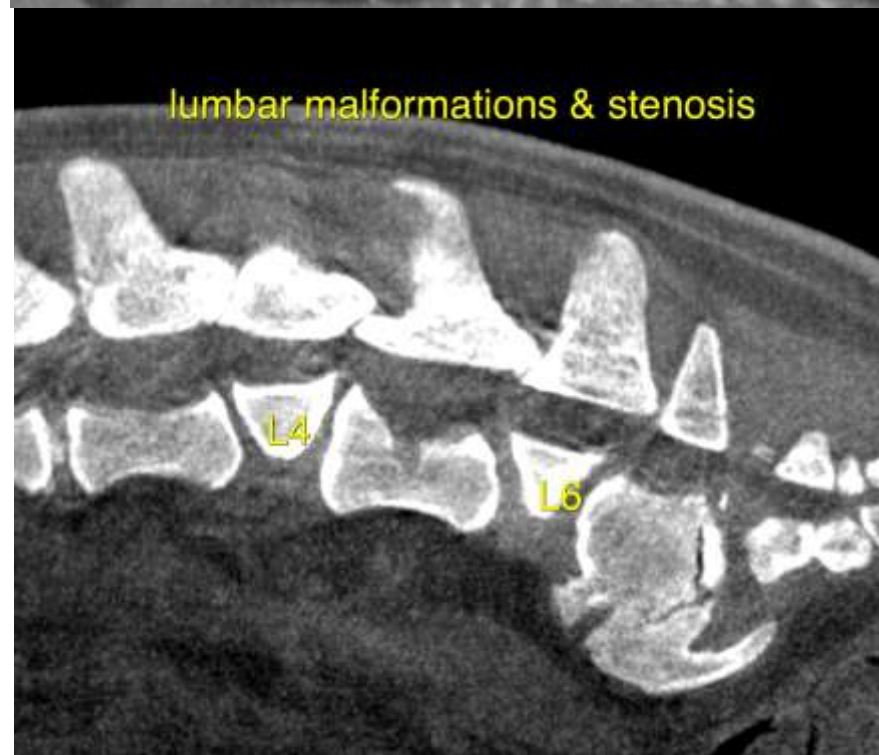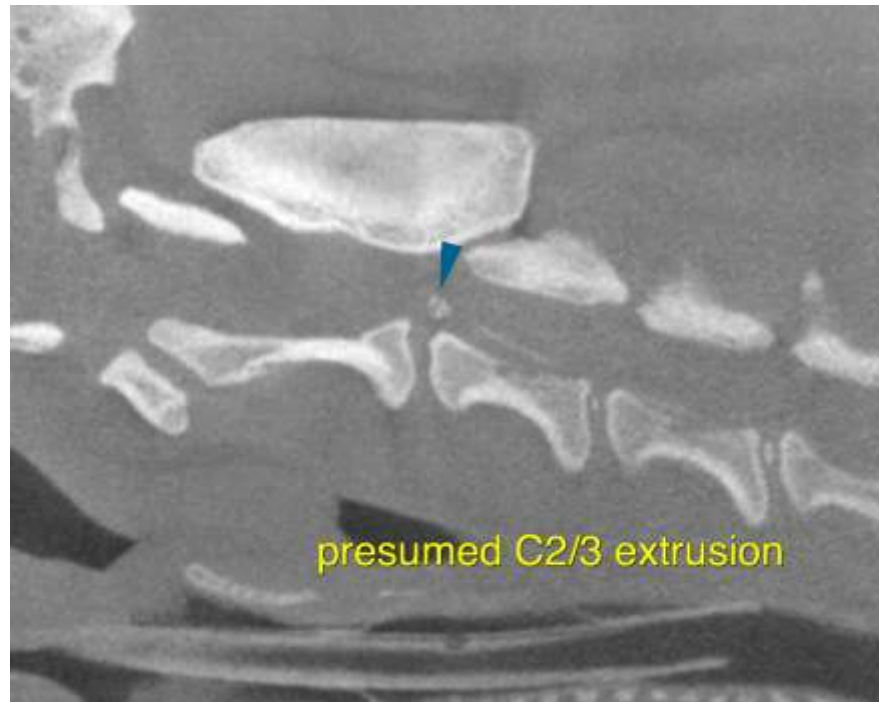Twins Veterinary
Hospital

INVOICE

49354

DATE

1-3-22





PATIENT

ROCCO FRANZESE

SPECIES

Canine

BREED

French Bulldog

SEX

MN

AGE

4 Years

INTERPRETED BY

Nele Eley, DVM
Dr. med. Vet. DipECVDI

HOSPITAL NAME

Animal Surgical
Center

REFERRING VET

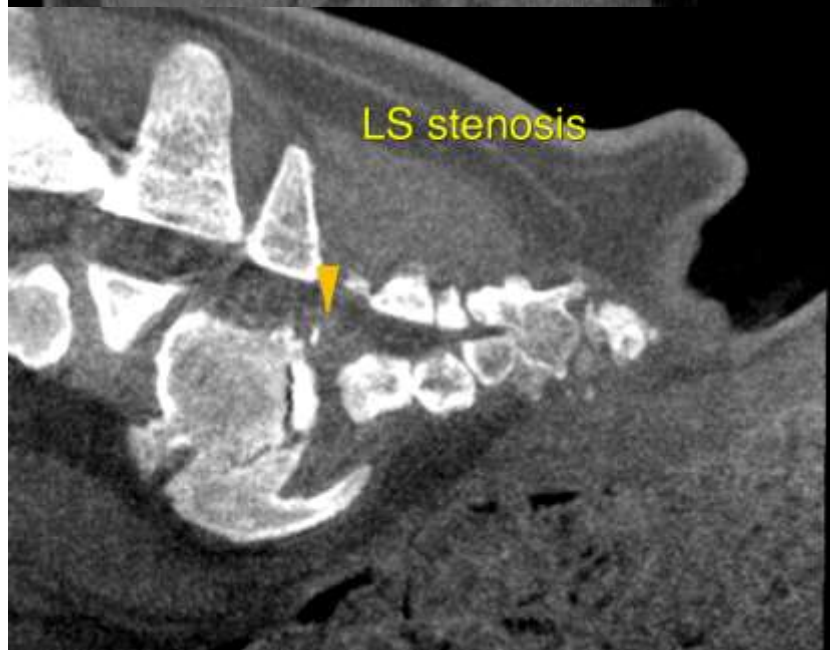
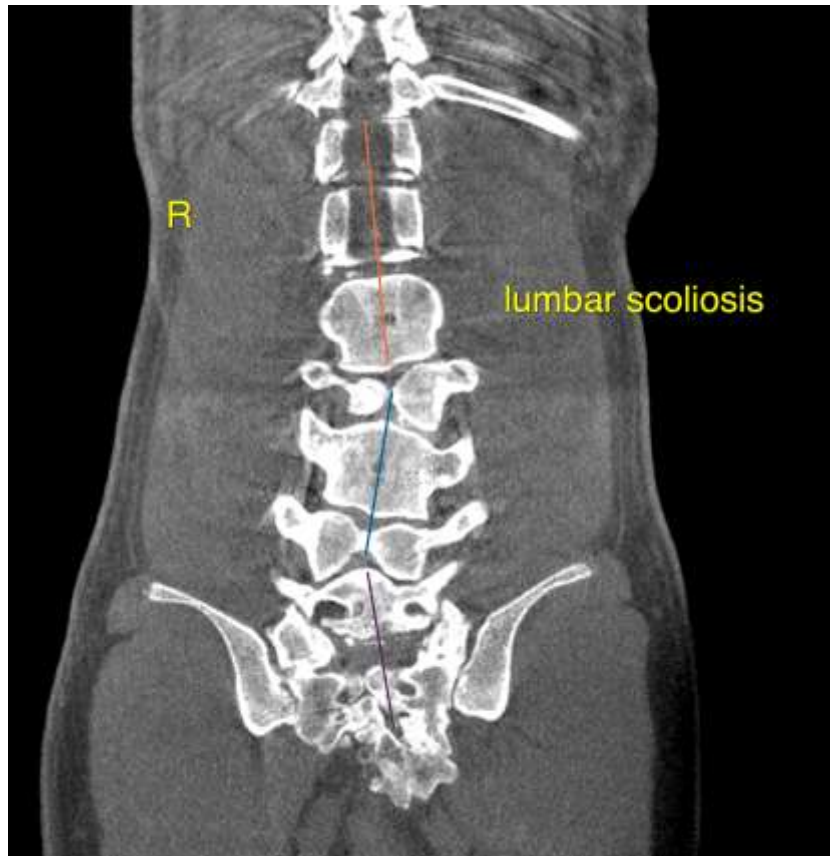
Twins Veterinary
Hospital

INVOICE

49354

DATE

1-3-22





PATIENT

The information and recommendations provided are based on the images presented by the referring veterinarian. No evaluation can be communicated regarding pathology that was not visible in the image/video clips provided.

ROCCO FRANZESE

SPECIES

Thank you for this referral. If the clinical or image interpretation does not parallel your findings or if I can be of any further assistance please contact me.

Canine

Nele Eley, DVM, Dr. med. vet., DipECVDI
European Specialist in Veterinary Diagnostic Imaging, Cert. Radiology,
Senior lecturer University of Giessen, Germany, Veterinary Faculty, Department of Radiology
Nele.Eley@sonopath.com

BREED

French Bulldog

SEX

MN

AGE

4 Years

INTERPRETED BY

Nele Eley, DVM
Dr. med. Vet. DipECVDI

HOSPITAL NAME

Animal Surgical
Center

REFERRING VET

Twins Veterinary
Hospital

INVOICE

49354

DATE

1-3-22