

**PATIENT**

Kola Postlewait

PRESENTING CLINICAL SIGNS

P presented for exam of mass present over R lateral rib cage. Per O, first noticed 2 weeks ago, has doubled in size since. P also recently started limping on RF limb. P has lost 10 pounds since last time he was weighed. Was 97# on 11/9/21, now 87. On exam, mass is very firm/hard, non moveable.

SPECIES

Canine

RADIOGRAPHIC STUDY OF THE THORAX

Right/left lateral and ventrodorsal views totaling 3 images available for review.

BREED

Rhodesian Ridgeback

RADIOGRAPHIC FINDINGS

A large soft tissue opaque mass is seen in the right lateral thoracic wall. The mass measures approximately 12.0 cm in diameter and presents extra- and well as intra- thoracic extension deviating the lung surface medially with an extra pleural sign. Aggressive osteolysis of the distal third of the 6th right rib is seen.

SEX

NM

The lung presents multiple small pulmonary interstitial nodules.

AGE

1.5 Years

RADIOGRAPHIC DIAGNOSIS

- Mass with aggressive osteolysis of the 6th right rib with large extra- and intra- thoracic soft tissue component.
- Nodular interstitial lung pattern.

INTERPRETED BY

Nele Eley, DVM
Dr. med. Vet. DipECVDI

INTERPRETATION OF THE FINDINGS & FURTHER RECOMMENDATIONS

The radiographic findings are highly suggestive for a malignant neoplasia of the 6th right rib such as osteosarcoma, chondrosarcoma, lymphosarcoma, or other. Unfortunately, the radiographic findings also suggest presence of multiple interstitial nodules compatible with pulmonary metastatic disease. For a final diagnosis, sampling of the mass could be considered.

HOSPITAL NAME

Grove Veterinary
Clinic

REFERRING VET

Dr. Wesley Pospichal

INVOICE

49277

DATE

1-3-22



PATIENT

Kola Postlewait

SPECIES

Canine

BREED

Rhodesian Ridgeback

SEX

NM

AGE

1.5 Years

INTERPRETED BY

Nele Eley, DVM
Dr. med. Vet. DipECVDI

HOSPITAL NAME

Grove Veterinary
Clinic

REFERRING VET

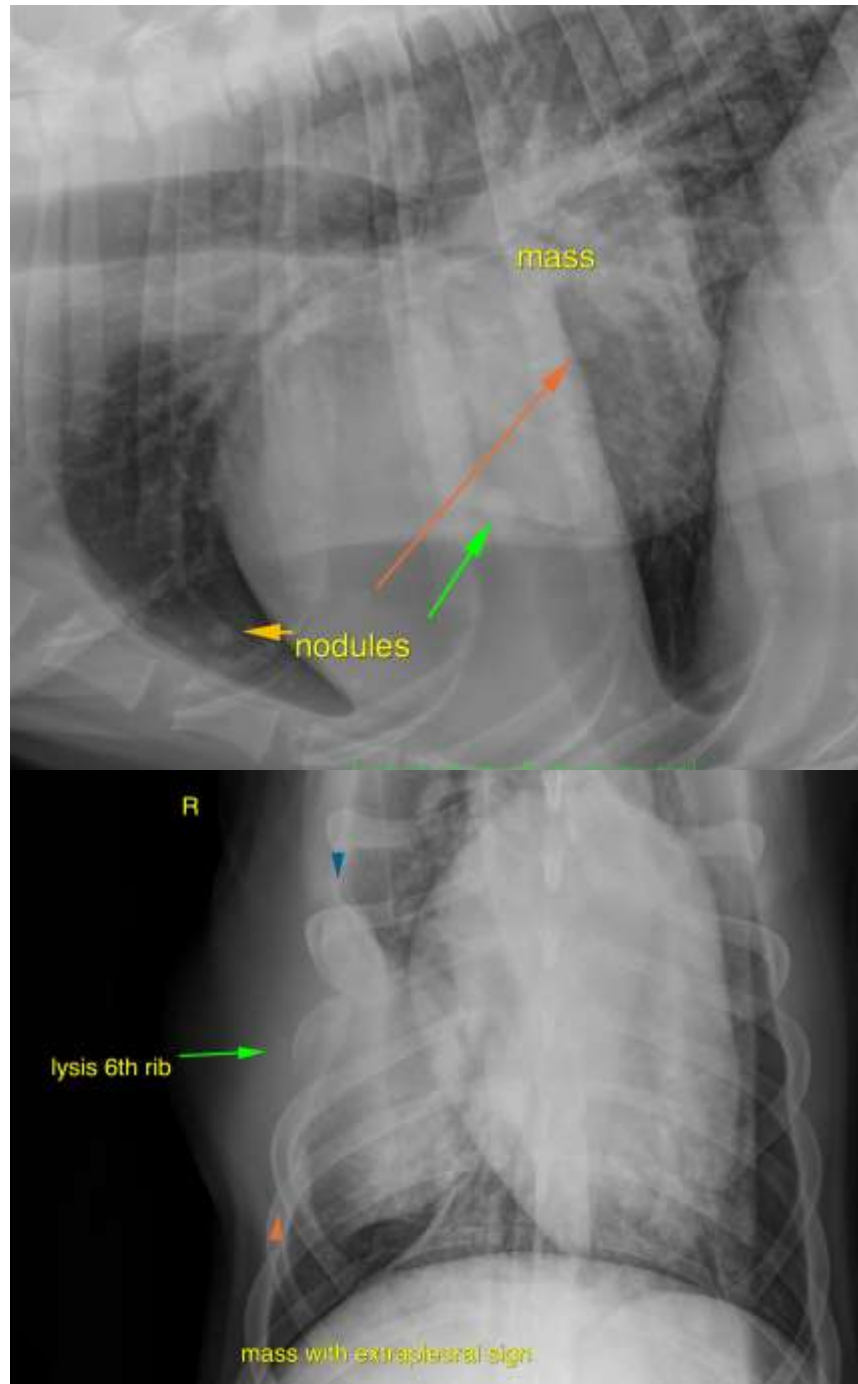
Dr. Wesley Pospichal

INVOICE

49277

DATE

1-3-22





PATIENT

Kola Postlewait

The information and recommendations provided are based on the images presented by the referring veterinarian. No evaluation can be communicated regarding pathology that was not visible in the image/video clips provided.

SPECIES

Canine

Thank you for this referral. If the clinical or image interpretation does not parallel your findings or if I can be of any further assistance please contact me.

BREED

Rhodesian Ridgeback

Nele Eley, DVM, Dr. med. vet., DipECVDI
European Specialist in Veterinary Diagnostic Imaging, Cert. Radiology,
Senior lecturer University of Giessen, Germany, Veterinary Faculty, Department of Radiology
Nele.Eley@sonopath.com

SEX

NM

AGE

1.5 Years

INTERPRETED BY

Nele Eley, DVM
Dr. med. Vet. DipECVDI

HOSPITAL NAME

Grove Veterinary
Clinic

REFERRING VET

Dr. Wesley Pospichal

INVOICE

49277

DATE

1-3-22