



## PATIENT

Briar Lopez

## SPECIES

Canine

## BREED

Catahoula Leopard  
Hound

## SEX

FS

## AGE

2Y

## WEIGHT

78lbs

## INTERPRETED BY

Nele Eley (Ondreka),  
DVM Dr. med. vet.,  
DipECVDI

## IMAGING PERFORMED BY

Mobile Pet Imaging

## HOSPITAL NAME

Mobile Pet Imaging

## REFERRING VET

Armstrong

## INVOICE

73541

## DATE

1-29-26

## PRESENTING CLINICAL SIGNS

History:

- Presenting complaint or concern (brief)
- Problem List/Comments:
- Facial swelling- r/o foreign body vs infectious vs neoplasia
- Please list any current medications
- Item Description Directions
- Omeprazole 20mg. Capsules Give 1 capsule orally every 12 hours until finished. ANTACID,
- Prednisone 20mg PO BID
- Doxycycline 300mg PO BID
- Provable 1 capsule SID
- Benadryl 75mg PO BID
- Does the patient have any allergies and/or drug reactions, in particular to iodine or anesthetic drugs? None noted

Abnormal PE/Chem/CBC/UA Results: PE- bar, pink moist, normal abd and thx, ptosis OD and eyeball seems sunken when compared

## COMPUTED TOMOGRAPHIC STUDY OF THE HEAD

Plain and post contrast studies are available for review.

## COMPUTED TOMOGRAPHIC FINDINGS

The CT study reveals a well delineated, multicavitated, fluid filled lesion measuring approximately 5 x 4 x 2.5 cm within the right masseter muscle. The lesion shows peripheral rim enhancement and is filled with fluid attenuating contrast negative content. No discrete foreign material can be identified. Regional soft tissue swelling is noted. A thin subcutaneous component of the lesion is present on the surface of the masseter muscle, however, most of the lesion is intramuscular.

Mild right sided retropharyngeal lymph node enlargement is noted.

No significant dental changes are seen.

The salivary glands appear within normal limits.

## COMPUTED TOMOGRAPHIC DIAGNOSIS

- Right masseter muscle intramuscular fluid filled cavitory lesion most consistent with a) abscess, b) atypical sialocele.
- Mild reactive right retropharyngeal lymphadenopathy.

## INTERPRETATION OF FINDINGS & FURTHER RECOMMENDATIONS

The lesion's multicavitated appearance and rim enhancement are suggestive of an infectious or inflammatory process such as an abscess. No discrete foreign body was visualized, however, migration of a small nonopaque foreign body cannot be excluded. Atypical presentation of a sialocele remains a differential. However, the imaging characteristics favor an abscess.

Mild right retropharyngeal lymphadenomegaly is likely reactive secondary to local inflammation.



**PATIENT**

Briar Lopez

**SPECIES**

Canine

**BREED**

Catahoula Leopard  
Hound

**SEX**

FS

**AGE**

2Y

**WEIGHT**

78lbs

**INTERPRETED BY**

Nele Eley (Ondreka),  
DVM Dr. med. vet.,  
DipECVDI

**IMAGING  
PERFORMED BY**

Mobile Pet Imaging

**HOSPITAL NAME**

Mobile Pet Imaging

**REFERRING VET**

Armstrong

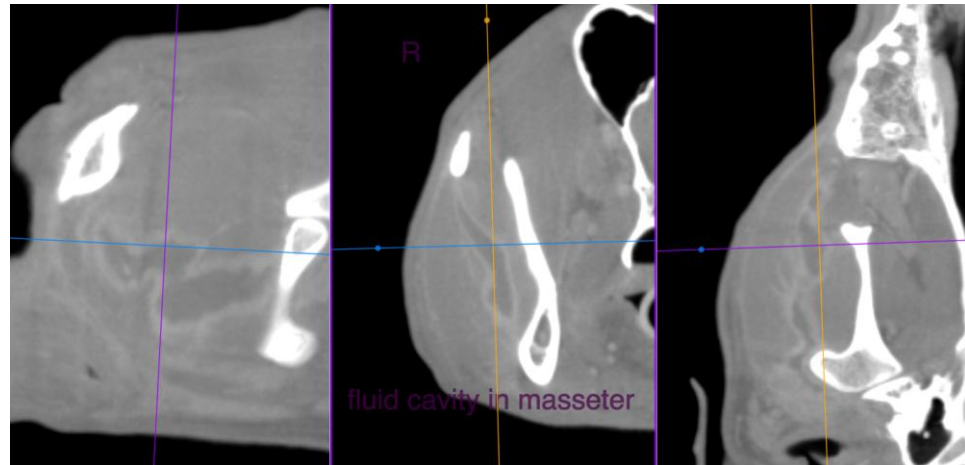
**INVOICE**

73541

**DATE**

1-29-26

Ultrasound guided or surgical sampling of the fluid for cytology culture and sensitivity is recommended to confirm tentative diagnosis.



The information and recommendations provided are based on the images presented by the referring veterinarian. No evaluation can be communicated regarding pathology that was not visible in the image/video clips provided.

Thank you for this referral. If the clinical or image interpretation does not parallel your findings or if I can be of any further assistance please contact me.

**Nele Eley (Ondreka)**, DVM, Dr. med. vet., DipECVDI  
European Specialist in Veterinary Diagnostic Imaging, Cert. Radiology,  
Senior lecturer University of Giessen/Germany, Veterinary Faculty, Department of Radiology.  
[info@sonopath.com](mailto:info@sonopath.com)