



PATIENT

Aura Adams

SPECIES

Feline

BREED

Maine Coon

SEX

Female

AGE

9M

WEIGHT

6.3

INTERPRETED BY

Nele Eley (Ondreka),
DVM Dr. med. vet.,
DipECVDI

IMAGING PERFORMED BY

Tiffany- CVT/ Dr. George

HOSPITAL NAME

Green Prairie Animal
Hospital

REFERRING VET

Dr. George Eales

INVOICE

73546

DATE

1-29-26

PRESENTING CLINICAL SIGNS

Head tilt to the left duration of about 4 weeks.

COMPUTED TOMOGRAPHIC STUDY OF THE HEAD

Plain and post contrast studies are available for review.

COMPUTED TOMOGRAPHIC FINDINGS

The left tympanic bulla contains fluid attenuating material with moderate generalized bulla wall thickening and sclerosis consistent with chronic otitis media. Abnormal soft tissue attenuation extending beyond the confines of the tympanic cavity is seen with contrast enhancement along the course of the left vestibulocochlear nerve as well as regional meningeal thickening with increased enhancement adjacent to the petrous temporal bone, concerning for intracranial extension of the inflammatory disease.

The right tympanic bulla and inner ear structures are unremarkable. Both external auditory meatuses present within normal limits.

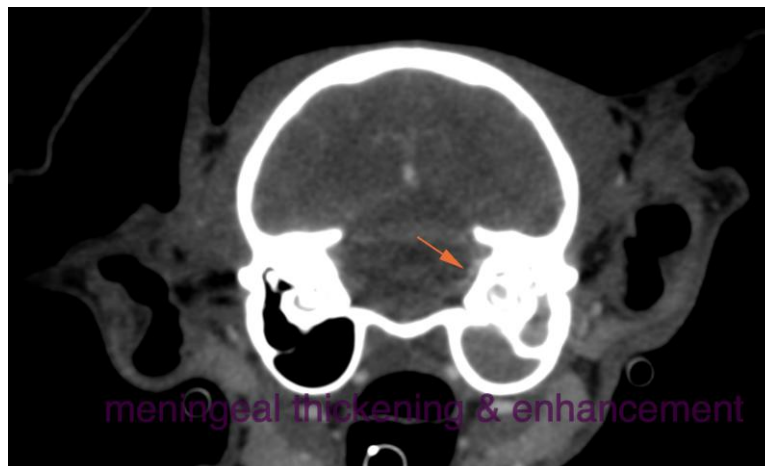The left retropharyngeal lymph node is mildly enlarged with preserved shape and internal architecture consistent with reactive lymphadenopathy.

COMPUTED TOMOGRAPHIC DIAGNOSIS

- Chronic left sided otitis media with suspected progression to otitis interna and intracranial extension.
- Suspect left vestibulocochlear nerve involvement.
- Mild left retropharyngeal lymphadenomegaly: most consistent with reactive change.

INTERPRETATION OF FINDINGS & FURTHER RECOMMENDATIONS

The imaging findings support the diagnosis of chronic progressive otitis media and interna on the left with intracranial extension and neurologic involvement likely explaining the vestibular signs. Aggressive medical management with culture directed antimicrobial therapy is recommended if feasible. Consider neurologic monitoring for progression of central signs.





PATIENT

Aura Adams

SPECIES

Feline

BREED

Maine Coon

SEX

Female

AGE

9M

WEIGHT

6.3

INTERPRETED BY

Nele Eley (Ondreka),
DVM Dr. med. vet.,
DipECVDI

IMAGING PERFORMED BY

Tiffany- CVT/ Dr. George

HOSPITAL NAME

Green Prairie Animal
Hospital

REFERRING VET

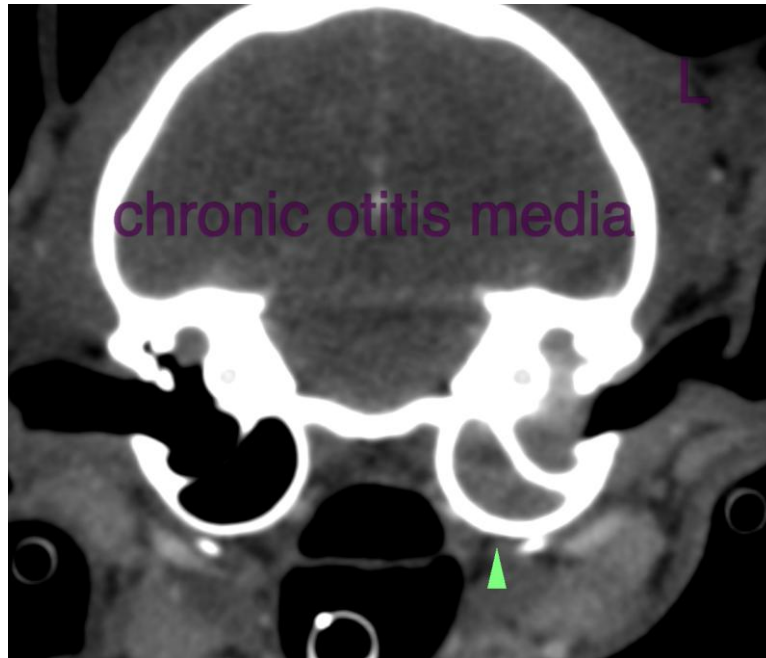
Dr. George Eales

INVOICE

73546

DATE

1-29-26



The information and recommendations provided are based on the images presented by the referring veterinarian. No evaluation can be communicated regarding pathology that was not visible in the image/video clips provided.

Thank you for this referral. If the clinical or image interpretation does not parallel your findings or if I can be of any further assistance please contact me.

Nele Eley (Ondreka), DVM, Dr. med. vet., DipECVDI
European Specialist in Veterinary Diagnostic Imaging, Cert. Radiology,
Senior lecturer University of Giessen/Germany, Veterinary Faculty, Department of Radiology.
info@sonopath.com