



PATIENT

Mac Grant

PRESENTING CLINICAL SIGNS

Presented for lameness of left FL for 1 week. Progressively worsened.
Abnormal PE/Chem/CBC/UA Results: Pain on palpation of proximal left humerus just distal to joint. No pain on extension or flexion of shoulder or elbow. No fever on examination. Rest of PE unremarkable. No BW at this time.

SPECIES

Canine

RADIOGRAPHIC STUDY OF THE LEFT SHOULDER

Mediolateral and caudocranial views of the left shoulder and mediolateral and craniocaudal views of the left elbow totaling 4 images available for review.

BREED

Golden Retriever

Interpretation of the shoulder requested.

SEX

Male

RADIOGRAPHIC FINDINGS

The subchondral bone surface of the left humeral head presents even and smooth. No evidence of subchondral bone defects or traumatic osseous injury is seen.

The medullary cavity of the left humerus presents multifocal sclerosis accentuating the proximal and distal metaphyseal portions of the bone.

AGE

8.8 Months

RADIOGRAPHIC DIAGNOSIS

- No evidence of pathology in the left shoulder joint.
- Suspect panosteitis eosinophilica.

INTERPRETED BY

Nele Eley, DVM
Dr. med. Vet. DipECVDI

INTERPRETATION OF THE FINDINGS & FURTHER RECOMMENDATIONS

The radiographic findings support the presence of panosteitis eosinophilica which is a self-limiting juvenile disorder associated with painful inflammation of the long bones and also termed “growing pains” colloquially. Resting the patient, systemic NSAID administration, and restriction of the daily caloric intake should help alleviate the clinical signs.

HOSPITAL NAME

Incline Veterinary
Hospital

There was no subchondral bone defect in the left humeral head seen. Osteochondritis is unlikely based on the negative radiographic findings, even though the visibility of smaller defects may depend on the positioning of the shoulder joint.

REFERRING VET

Abby Mulchi

INVOICE

56448

DATE

1-29-23



PATIENT

Mac Grant

SPECIES

Canine

BREED

Golden Retriever

SEX

Male

AGE

8.8 Months

INTERPRETED BY

Nele Eley, DVM
Dr. med. Vet. DipECVDI

HOSPITAL NAME

Incline Veterinary
Hospital

REFERRING VET

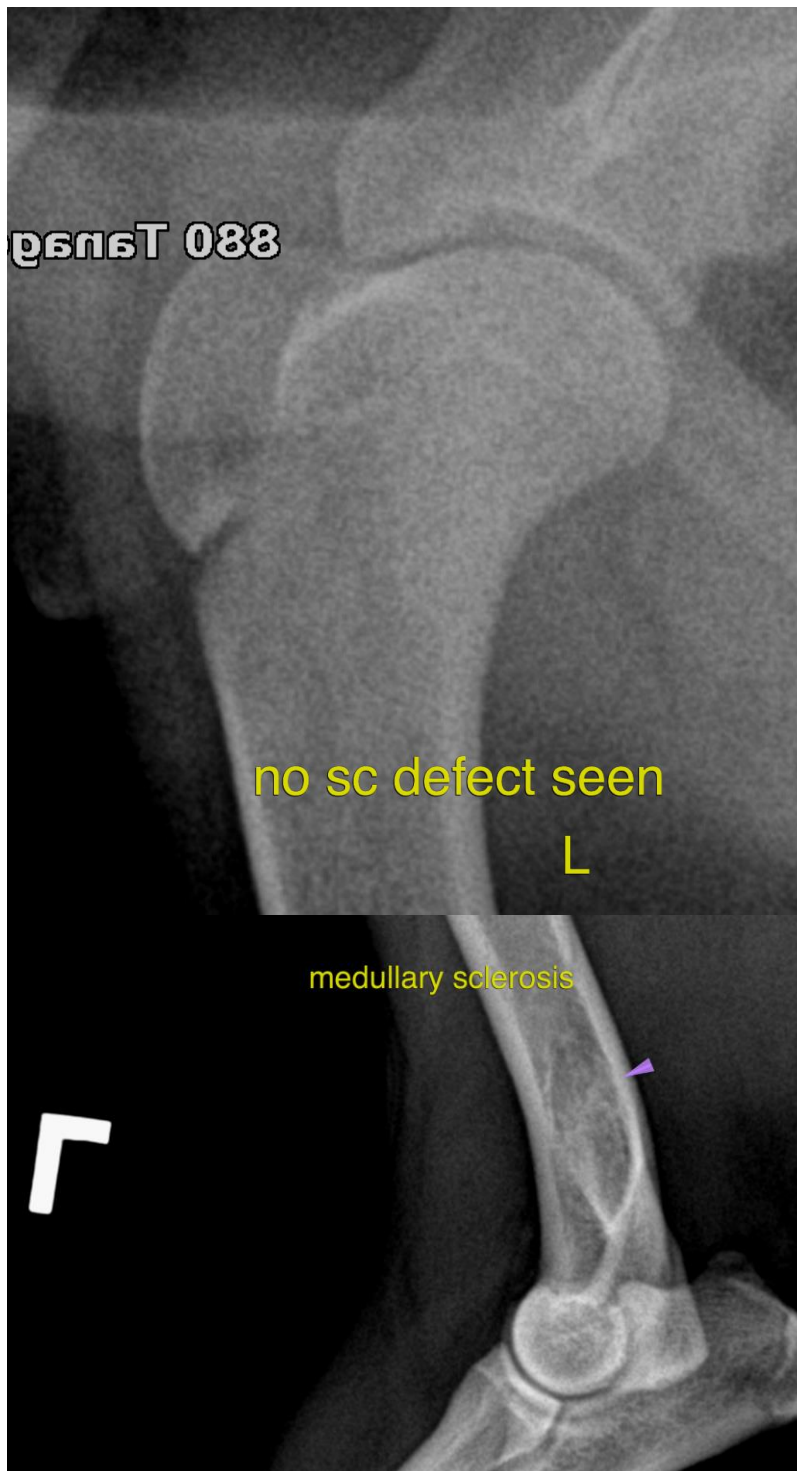
Abby Mulchi

INVOICE

56448

DATE

1-29-23





PATIENT

Mac Grant

The information and recommendations provided are based on the images presented by the referring veterinarian/sonographer. No evaluation can be communicated regarding pathology that was not visible in the image/video clips provided.

Thank you for this referral. If the clinical or image interpretation does not parallel your findings or if I can be of any further assistance please contact me.

SPECIES

Canine

Nele Eley, DVM, Dr. med. vet., DipECVDI
European Specialist in Veterinary Diagnostic Imaging, Cert. Radiology,
Senior lecturer University of Giessen, Germany, Veterinary Faculty, Department of Radiology
Nele.Eley@sonopath.com

BREED

Golden Retriever

SEX

Male

AGE

8.8 Months

INTERPRETED BY

Nele Eley, DVM
Dr. med. Vet. DipECVDI

HOSPITAL NAME

Incline Veterinary
Hospital

REFERRING VET

Abby Mulchi

INVOICE

56448

DATE

1-29-23