



PATIENT

Lily Wilson-Pote

SPECIES

Feline

BREED

DSH

SEX

Female Spayed

AGE

12 Years

INTERPRETED BY

Nele Eley, DVM
Dr. med. Vet. DipECVDI

HOSPITAL NAME

St. Catherine's Animal
Hospital

REFERRING VET

Dr. Masoud

INVOICE

49956

DATE

1-29-22

PRESENTING CLINICAL SIGNS

vomiting since wed, not using litter box for pee or poo, growling when she eats and then vomits
Abnormal PE/Chem/CBC/UA Results: Dehydrated , lethargic , sever abdominal distention
very painful to touch , bladder is moderately distended , urine was collected by cystocentesis ,
urine very concentrated and smells .BW: monocytopenia , Eosinopenia , T. protein elevated ,
hyperglycemia , fPL: elevated , T4: WNL

RADIOGRAPHIC STUDY OF THE ABDOMEN

Right/left lateral and ventrodorsal whole body views totaling 3 images available for review.

Abdominal read requested.

RADIOGRAPHIC FINDINGS

The urinary bladder is severely distended. No evidence of radiopaque calculi is seen.

The stomach presents moderate aerophagia.

The small intestinal loops are evenly distributed throughout the mid abdomen. No evidence of
abnormal dilation, plication, or radiopaque foreign material is seen.

The colon contains a moderate amount of fecal material.

RADIOGRAPHIC DIAGNOSIS

- Gastric aerophagia.

INTERPRETATION OF THE FINDINGS & FURTHER RECOMMENDATIONS

The radiographic study reveals presence of gas within the stomach which may be due to
swallowing of air; however, functional ileus such as with pancreatopathy and/or gastropathy is a
potential as well and further definition by means of ultrasound should be considered, especially in
presence of increased LPI in order to rule out underlying pancreatitis.



PATIENT

Lily Wilson-Pote

SPECIES

Feline

BREED

DSH

SEX

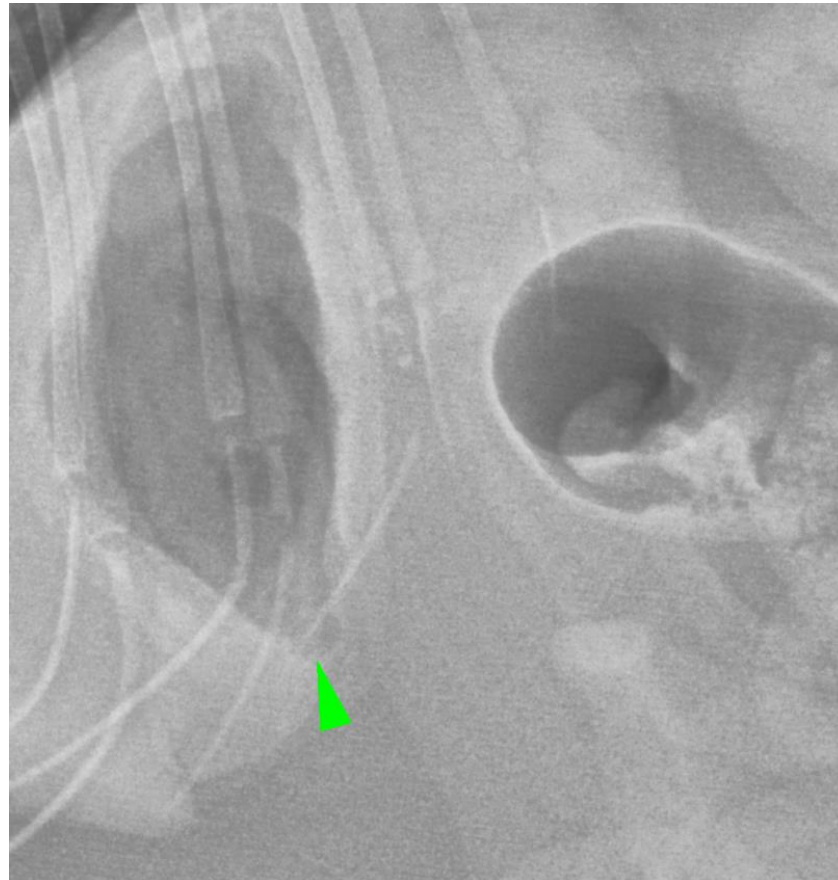
Female Spayed

AGE

12 Years

INTERPRETED BY

Nele Eley, DVM
Dr. med. Vet. DipECVDI



HOSPITAL NAME

St. Catherine's Animal
Hospital

REFERRING VET

Dr. Masoud

INVOICE

49956

DATE

1-29-22

The information and recommendations provided are based on the images presented by the referring veterinarian/sonographer. No evaluation can be communicated regarding pathology that was not visible in the image/video clips provided.

Thank you for this referral. If the clinical or image interpretation does not parallel your findings or if I can be of any further assistance please contact me.

Nele Eley, DVM, Dr. med. vet., DipECVDI
European Specialist in Veterinary Diagnostic Imaging, Cert. Radiology,
Senior lecturer University of Giessen, Germany, Veterinary Faculty, Department of Radiology
Nele.Eley@sonopath.com