



PATIENT

Hermione Hall

PRESENTING CLINICAL SIGNS

inappetence and vomiting for 4 days , owner mentioned that cat was playing with a piece of carpet
Abnormal PE/Chem/CBC/UA Results: significant elevation of BUN , CREA , PH and K (acute kidney failure)

SPECIES

Feline

RADIOGRAPHIC STUDY OF THE ABDOMEN

Right/left lateral and ventrodorsal full body views totaling 3 images available for review.

Abdominal read requested.

BREED

Domestic Longhair

RADIOGRAPHIC FINDINGS

The surrounding bony structures are within normal limits.

SEX

Female

No abnormalities of the extraabdominal soft tissues are noted. The abdominal wall is smooth and thin.

The serosal detail is maintained throughout the peritoneal and retroperitoneal space.

AGE

5 Months

The liver is appropriate in position, size and presents uniform opacity.

The splenic head is in the anticipated position and within normal limits for size and opacity. The splenic tail is not seen.

INTERPRETED BY

Nele Eley, DVM
Dr. med. Vet. DipECVDI

Both kidneys are seen and present with normal size, shape, delineation and opacity. The urinary bladder is in its anticipated position. No radiopaque calculi are noted throughout the upper and lower urinary tract.

A mild amount of fluid and gas is present within the stomach.

HOSPITAL NAME

St. Catherine's Animal
Hospital

The small intestinal loops are evenly distributed throughout the mid abdomen. Corrugation of one small intestinal loop in the ventral abdomen and a discrepant small intestinal gas pattern are present. No evidence of radiopaque foreign material is seen.

There is a moderate amount of inspissated fecal material within the colon mainly within the descending colon.

REFERRING VET

Dr. Boctor

RADIOGRAPHIC DIAGNOSIS

- Corrugated small intestine and maldigestion pattern.

INVOICE

49958

INTERPRETATION OF THE FINDINGS & FURTHER RECOMMENDATIONS

No overt evidence of mechanical ileus is seen; however, it has to be noted that ileus with foreign material can be radiographically occult. The corrugated loop and discrepant gas pattern may simply be an expression of gastroenteropathy. However, plication with linear foreign material cannot be ruled out entirely and abdominal ultrasound is strongly recommended if not performed already.

DATE

1-29-22

The radiographic presentation of the kidneys is within normal limits.



PATIENT

Hermione Hall

SPECIES

Feline

BREED

Domestic Longhair

SEX

Female

AGE

5 Months

INTERPRETED BY

Nele Eley, DVM
Dr. med. Vet. DipECVDI

HOSPITAL NAME

St. Catherine's Animal
Hospital

REFERRING VET

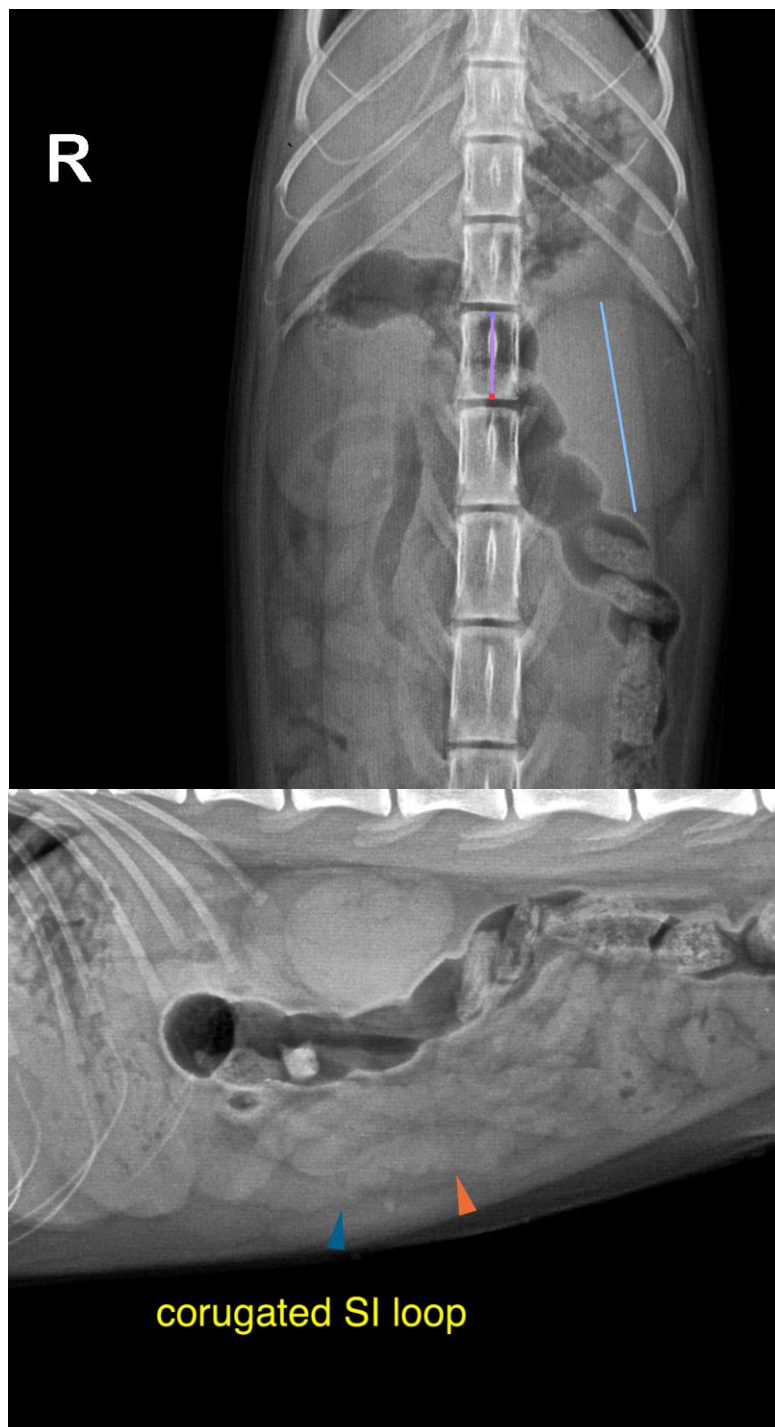
Dr. Boctor

INVOICE

49958

DATE

1-29-22





PATIENT

Hermione Hall

The information and recommendations provided are based on the images presented by the referring veterinarian/sonographer. No evaluation can be communicated regarding pathology that was not visible in the image/video clips provided.

SPECIES

Feline

Thank you for this referral. If the clinical or image interpretation does not parallel your findings or if I can be of any further assistance please contact me.

BREED

Domestic Longhair

Nele Eley, DVM, Dr. med. vet., DipECVDI
European Specialist in Veterinary Diagnostic Imaging, Cert. Radiology,
Senior lecturer University of Giessen, Germany, Veterinary Faculty, Department of Radiology
Nele.Eley@sonopath.com

SEX

Female

AGE

5 Months

INTERPRETED BY

Nele Eley, DVM
Dr. med. Vet. DipECVDI

HOSPITAL NAME

St. Catherine's Animal
Hospital

REFERRING VET

Dr. Boctor

INVOICE

49958

DATE

1-29-22