



PATIENT

Purrsephone Gannon

SPECIES

Feline

BREED

Balinese

SEX

FS

AGE

10M

WEIGHT

3.4kg

INTERPRETED BY

Nele Eley (Ondreka),
DVM Dr. med. vet.,
DipECVDI

IMAGING PERFORMED BY

RVT

HOSPITAL NAME

Windermere
Veterinary Hospital

REFERRING VET

Dr. Dani Wood

INVOICE

73518

DATE

1-28-26

PRESENTING CLINICAL SIGNS

chronic dry hacking cough for a few months, started after spay in September 2025, trial with Clavamox and Prednisolone in November - improved but still having a coughing episode 1-2 times per week, on one of the lateral views tracheal collapse?

RADIOGRAPHIC STUDY OF THE THORAX

Multiple orthogonal views totaling 6 images available for review.

RADIOGRAPHIC FINDINGS

A moderate generalized bronchial lung pattern is noted throughout the lungs consistent with chronic bronchial inflammation. No focal pulmonary consolidation, mass, or nodules are identified.

Tracheal diameter appears within normal limits. No true tracheal collapse is appreciated. Apparent narrowing on lateral views is likely due to head/neck positioning or rotational artifact.

The cardiac silhouette presents within normal limits for size and morphology. The VHS is 7.0 approximately. The pulmonary vessels appear normal.

The pleural space and mediastinum present normal in contour and opacity.

No thoracic wall abnormalities are identified.

RADIOGRAPHIC DIAGNOSIS

- Moderate generalized bronchial lung pattern.
- No radiographic evidence of tracheal collapse.
- Heart size and mediastinal structures present normal.

INTERPRETATION OF FINDINGS & FURTHER RECOMMENDATIONS

The imaging findings are most consistent with chronic inflammatory bronchial disease which may correspond to feline chronic bronchitis or allergic airway disease. Continued management with anti-inflammatory therapy can be considered. Environmental management to reduce airway irritants such as smoke, dust, and aerosols is recommended if not performed already. Consider bronchodilator therapy. Airway cytology/bronchoscopy may be indicated to further define should the patient's response to the initiated medical management remain partial.



PATIENT

Purrsephone Gannon

SPECIES

Feline

BREED

Balinese

SEX

FS

AGE

10M

WEIGHT

3.4kg

INTERPRETED BY

Nele Eley (Ondreka),
DVM Dr. med. vet.,
DipECVDI

IMAGING PERFORMED BY

RVT

HOSPITAL NAME

Windermere
Veterinary Hospital

REFERRING VET

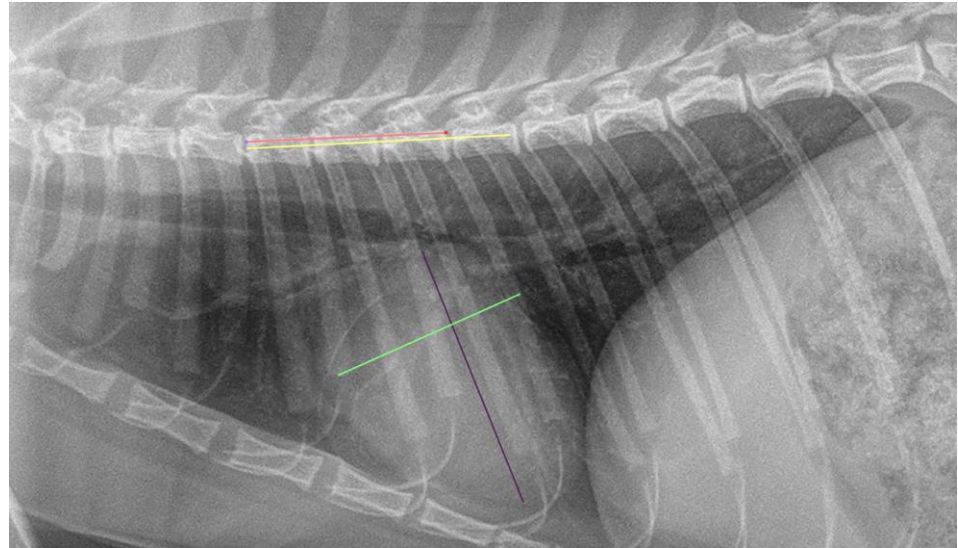
Dr. Dani Wood

INVOICE

73518

DATE

1-28-26



The information and recommendations provided are based on the images presented by the referring veterinarian. No evaluation can be communicated regarding pathology that was not visible in the image/video clips provided.

Thank you for this referral. If the clinical or image interpretation does not parallel your findings or if I can be of any further assistance please contact me.

Nele Eley (Ondreka), DVM, Dr. med. vet., DipECVDI
European Specialist in Veterinary Diagnostic Imaging, Cert. Radiology,
Senior lecturer University of Giessen/Germany, Veterinary Faculty, Department of Radiology.
info@sonopath.com