

**PATIENT**

Ringo Andrade

PRESENTING CLINICAL SIGNS

Swelling on R side head/caudal mandible, duration ~3 weeks. Initially responded to amoxicillin but recurred once amoxicillin was stopped (they since re-started it). We are looking for a cause for the swelling.

SPECIES

Canine

Abnormal PE/Chem/CBC/UA Results: BW was completely normal.

BREED

Golden Doodle Mix

COMPUTED TOMOGRAPHIC STUDY OF THE HEAD & NECK

Plain and post contrast studies available for review.

COMPUTED TOMOGRAPHIC FINDINGS

The CT study reveals extensive cellulitis in the right mandibular angle and right side of the face.

SEX

MN

Moderate generalized enlargement of the right parotid salivary gland with diffuse delineation of the glands margin is seen. Nonuniform decrease in attenuation and enhancement is seen on the plain and post contrast studies within the glands tissue. The right parotid salivary duct presents moderate generalized dilation with moderate generalized thickening of its lining with increased contrast enhancement and extensive peripheral cellulitis.

AGE

3 Years

The right submandibular and retropharyngeal lymph nodes present moderate symmetric enlargement.

INTERPRETED BY

Nele Eley, DVM
Dr. med. Vet. DipECVDI

COMPUTED TOMOGRAPHIC DIAGNOSIS

- Right hand sided parotid salivary gland sialadenitis and ductilitis with extensive peripheral cellulitis and regional lymphadenitis.

INTERPRETATION OF THE FINDINGS & FURTHER RECOMMENDATIONS

Severe inflammation and moderate dilation of the right parotid salivary duct are seen and concurred by sialadenitis of the right parotid salivary gland, regional cellulitis, and regional lymphadenitis. Obstructive pathology of the duct through sialolithiasis or other cannot be seen. Ascending infection cannot be ruled out entirely however idiopathic inflammation is the most common cause of parotid sialadenitis.

HOSPITAL NAME

Animal Health Care
Denver

REFERRING VET

Cathryn Sayer

INVOICE

56422

DATE

1-28-23



PATIENT

Ringo Andrade

SPECIES

Canine

BREED

Golden Doodle Mix

SEX

MN

AGE

3 Years

INTERPRETED BY

Nele Eley, DVM
Dr. med. Vet. DipECVDI

HOSPITAL NAME

Animal Health Care
Denver

REFERRING VET

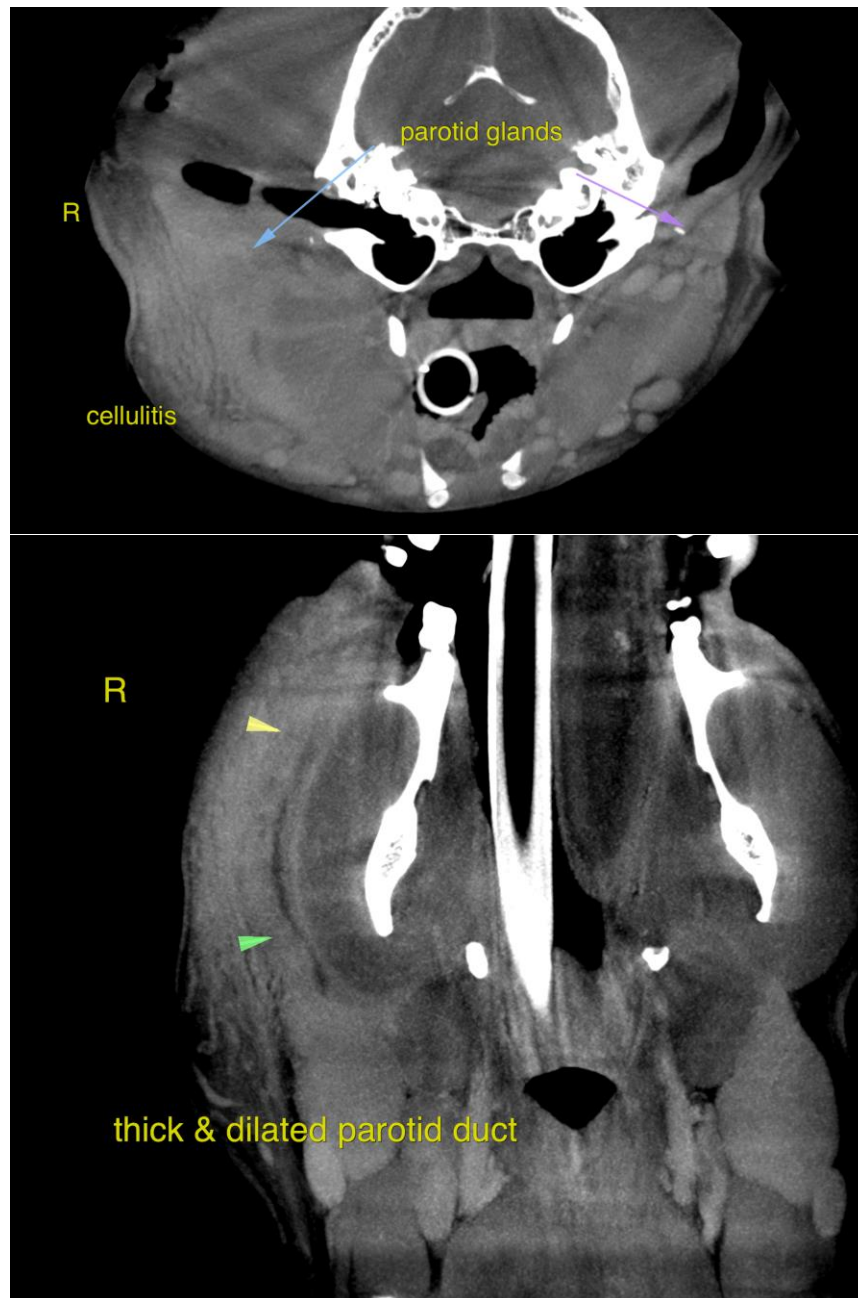
Cathryn Sayer

INVOICE

56422

DATE

1-28-23





PATIENT

Ringo Andrade

The information and recommendations provided are based on the images presented by the referring veterinarian/sonographer. No evaluation can be communicated regarding pathology that was not visible in the image/video clips provided.

Thank you for this referral. If the clinical or image interpretation does not parallel your findings or if I can be of any further assistance please contact me.

SPECIES

Canine

Nele Eley, DVM, Dr. med. vet., DipECVDI
European Specialist in Veterinary Diagnostic Imaging, Cert. Radiology,
Senior lecturer University of Giessen, Germany, Veterinary Faculty, Department of Radiology
Nele.Eley@sonopath.com

BREED

Golden Doodle Mix

SEX

MN

AGE

3 Years

INTERPRETED BY

Nele Eley, DVM
Dr. med. Vet. DipECVDI

HOSPITAL NAME

Animal Health Care
Denver

REFERRING VET

Cathryn Sayer

INVOICE

56422

DATE

1-28-23