



**PATIENT**

Baby Camacho

**SPECIES**

Canine

**BREED**

Shihtzu Mix

**SEX**

Female Intact

**AGE**

11 Years, 9 Months

**INTERPRETED BY**

Nele Eley, DVM  
Dr. med. Vet. DipECVDI

**HOSPITAL NAME**

The Pet Hospital of  
Stratford

**REFERRING VET**

Dr. Claudia Giuliani,  
DVM

**INVOICE**

56421

**DATE**

1-28-23

**PRESENTING CLINICAL SIGNS**

P presents for radiographs post BW and urinalysis. Urine showed ammonium phosphate and amorphous phosphate crystals. P is intact - recently had heat (may still be in heat but unsure) - drops of blood found at home that look creamy. P is lethargic. No vomiting. Eating/drinking well.

**RADIOGRAPHIC STUDY OF THE ABDOMEN**

Right/left lateral and ventrodorsal views of the abdomen totaling 3 images available for review.

**RADIOGRAPHIC FINDINGS**

The ventral abdominal wall appears slightly pendulous.

The mamils are prominent.

The stomach is postprandial.

The liver margins are slightly beyond the costal arch but pointed.

The kidneys present within expected limits.

No significant uterine body or uterine horn enlargement can be detected.

The urinary bladder is mildly distended.

The abdominal serosal detail appears to be maintained.

Severe intervertebral disc space collapse with vertebral end plate sclerosis and spondylosis deformans is seen between L2 and L3.

The patient is mildly obese.

**RADIOGRAPHIC DIAGNOSIS**

- No significant uterine enlargement seen.
- Postprandial gastrointestinal tract.
- Chronic intervertebral disc disease with spondylosis deformans L2/3.

**INTERPRETATION OF THE FINDINGS & FURTHER RECOMMENDATIONS**

No uterine enlargement can be appreciated. The radiographic sensitivity for pathology of the uterus and ovaries is limited however at this point there appears to be no significant uterine enlargement. Further definition by means of ultrasound should be considered in case of persisting clinical signs.

The L2/3 intervertebral disc disease appears to be chronic and may be concurred by compressive disc hernia. However, non-compressive uncomplicated degenerative disc disease is a potential too.



**PATIENT**

Baby Camacho

**SPECIES**

Canine

**BREED**

Shihtzu Mix

**SEX**

Female Intact

**AGE**

11 Years, 9 Months

**INTERPRETED BY**

Nele Eley, DVM  
Dr. med. Vet. DipECVDI

**HOSPITAL NAME**

The Pet Hospital of  
Stratford

**REFERRING VET**

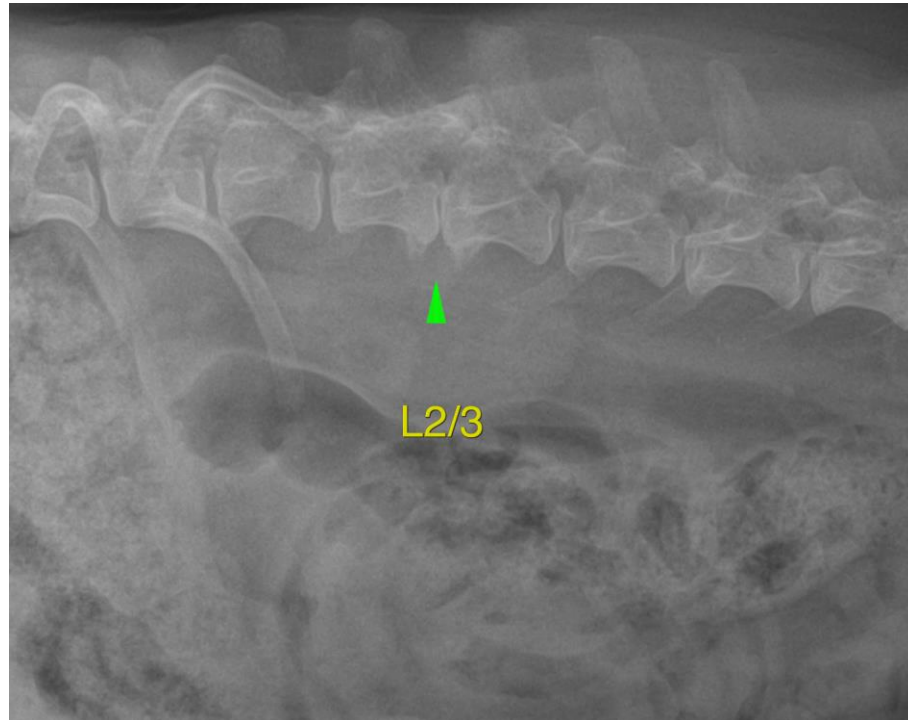
Dr. Claudia Giuliani,  
DVM

**INVOICE**

56421

**DATE**

1-28-23



The information and recommendations provided are based on the images presented by the referring veterinarian/sonographer. No evaluation can be communicated regarding pathology that was not visible in the image/video clips provided.

Thank you for this referral. If the clinical or image interpretation does not parallel your findings or if I can be of any further assistance please contact me.

**Nele Eley**, DVM, Dr. med. vet., DipECVDI  
European Specialist in Veterinary Diagnostic Imaging, Cert. Radiology,  
Senior lecturer University of Giessen, Germany, Veterinary Faculty, Department of Radiology  
Nele.Eley@sonopath.com