



PATIENT

Bodie Gentile

SPECIES

Canine

BREED

Border Collie

SEX

MN

AGE

8Y

WEIGHT

23kg

INTERPRETED BY

Nele Eley (Ondreka),
DVM Dr. med. vet.,
DipECVDI

IMAGING PERFORMED BY

David Lane

HOSPITAL NAME

Points East West
Veterinary Services

REFERRING VET

David Lane

INVOICE

73492

DATE

1-27-26

PRESENTING CLINICAL SIGNS

Prior LFL fMCP treated arthroscopically years ago, progressing to advanced OA currently. Injected PRP and HA into the elbow which engendered a partial response in that the lameness persists but the elbow is no longer sore on palpation. However, the carpal flexor tendons distal to the elbow (and just caudal to the humeral epicondyle) are consistently painful on palpation.

ULTRASONOGRAPHIC FINDINGS

Left Elbow

Moderate osteophytes and enthesiophytes are seen at the medial aspect of the left elbow joint and medial humeral condyle and epicondyle. Moderate synovial swelling and anechoic joint effusion are noted.

The flexor tendon origin presents mild to moderate overall swelling with slightly decreased echogenicity adjacent to the epicondyle and mildly obscured yet maintained fiber pattern.

The left biceps tendon passes over osteophytes. Tendon structure appears otherwise intact with no discrete tears or disruptions.

Right Elbow

Mild periarticular bone remodeling is noted. Mild enthesiophytes are present in the medial humeral epicondyle.

The flexor tendon echotexture and echogenicity present within normal limits.

The right biceps tendon presents within normal limits.

ULTRASONOGRAPHIC DIAGNOSIS

- History of medial coronoid pathology, moderate osteoarthritis with associated synovitis and effusion, and chronic secondary/concomitant flexor enthesiopathy of the left elbow.
- Mild degenerative changes of the right elbow.

INTERPRETATION OF FINDINGS & FURTHER RECOMMENDATIONS

The ultrasonographic findings are compatible with moderate chronic secondary/concomitant flexor enthesiopathy of the left elbow in conjunction with long standing osteoarthritis after medial coronoid pathology. Mild impingement of the biceps tendon may be present owing to anatomic interference and mechanical irritation with osteophytes. The biceps tendon shows adaptation over osteophytes, but no structural tear is identified. Consider continued multimodal therapy including anti-inflammatory, biological, and physical therapy.



PATIENT

Bodie Gentile

SPECIES

Canine

BREED

Border Collie

SEX

MN

AGE

8Y

WEIGHT

23kg

INTERPRETED BY

Nele Eley (Ondreka),
DVM Dr. med. vet.,
DipECVDP

IMAGING PERFORMED BY

David Lane

HOSPITAL NAME

Points East West
Veterinary Services

REFERRING VET

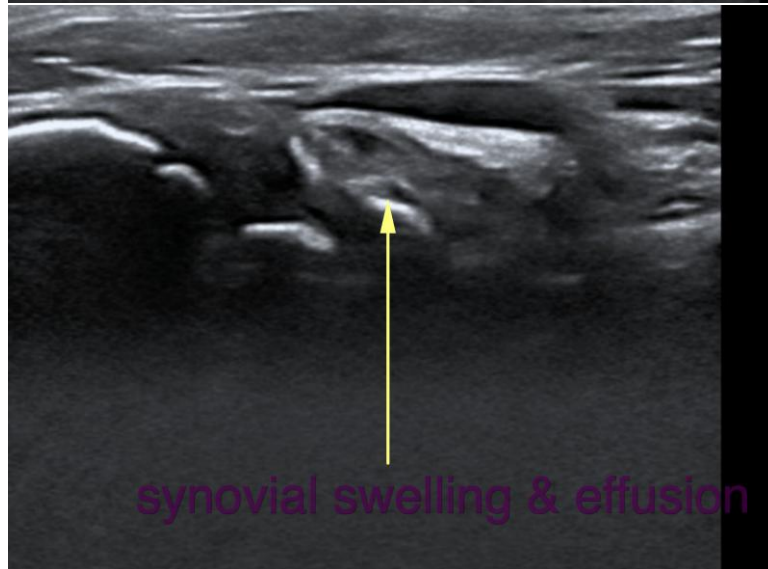
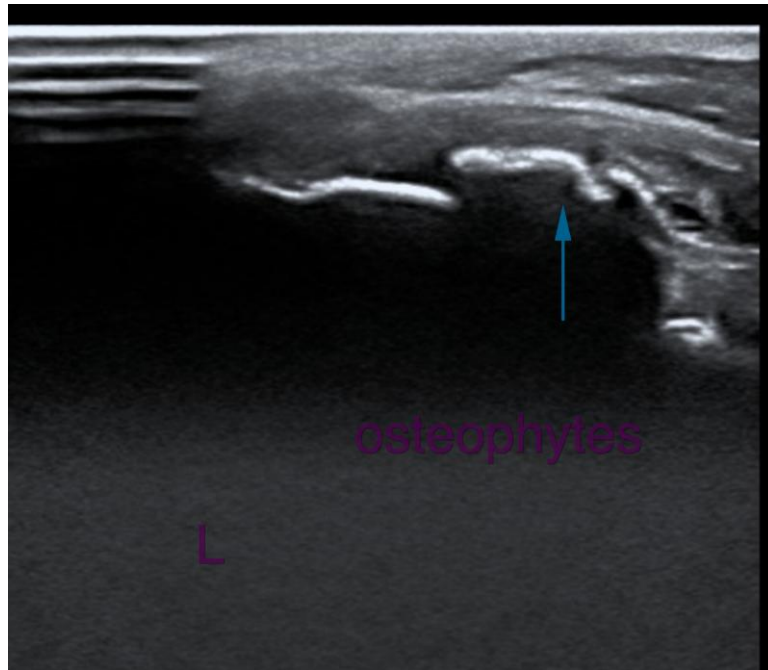
David Lane

INVOICE

73492

DATE

1-27-26





PATIENT

Bodie Gentile

SPECIES

Canine

BREED

Border Collie

SEX

MN

AGE

8Y

WEIGHT

23kg

INTERPRETED BY

Nele Eley (Ondreka),
DVM Dr. med. vet.,
DipECVDI

IMAGING PERFORMED BY

David Lane

HOSPITAL NAME

Points East West
Veterinary Services

REFERRING VET

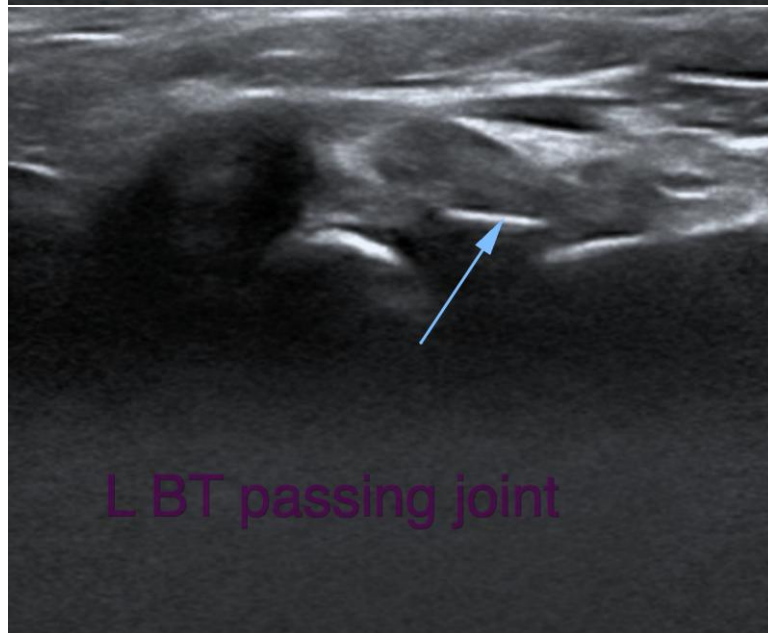
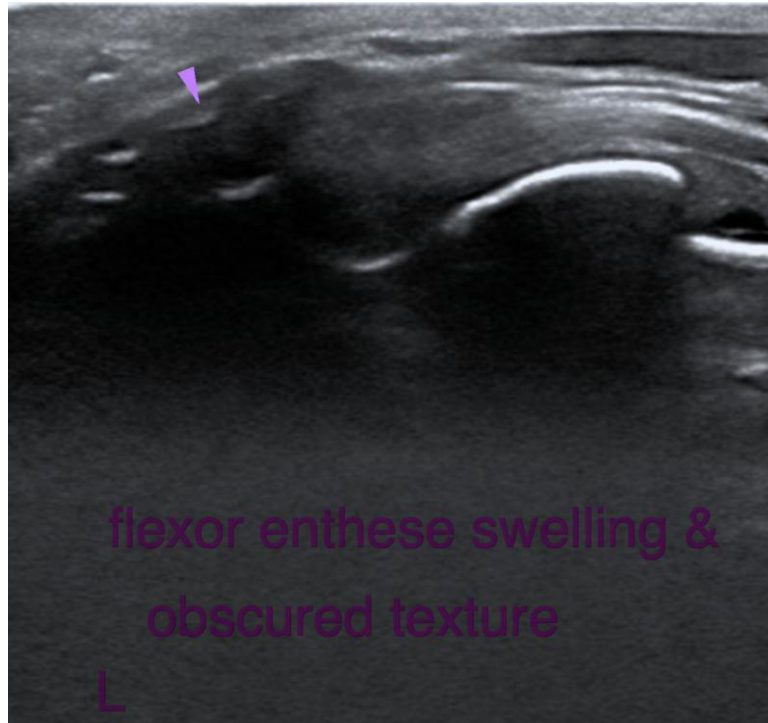
David Lane

INVOICE

73492

DATE

1-27-26





PATIENT

Bodie Gentile

SPECIES

Canine

BREED

Border Collie

SEX

MN

AGE

8Y

WEIGHT

23kg

INTERPRETED BY

Nele Eley (Ondreka),
DVM Dr. med. vet.,
DipECVDI

IMAGING PERFORMED BY

David Lane

HOSPITAL NAME

Points East West
Veterinary Services

REFERRING VET

David Lane

INVOICE

73492

DATE

1-27-26

The information and recommendations provided are based on the images presented by the referring veterinarian. No evaluation can be communicated regarding pathology that was not visible in the image/video clips provided.

Thank you for this referral. If the clinical or image interpretation does not parallel your findings or if I can be of any further assistance please contact me.

Nele Eley (Ondreka), DVM, Dr. med. vet., DipECVDI

European Specialist in Veterinary Diagnostic Imaging, Cert. Radiology,
Senior lecturer University of Giessen/Germany, Veterinary Faculty, Department of Radiology.
info@sonopath.com