



PATIENT PRESENTING CLINICAL SIGNS

PATIENT
Quila Molina
Pt Started having thick pink tinged discharge from nipples yesterday. Today Vaginal d/c of similar characteristic. Heart issue dx 1 year ago, no echo. On Pimobendan, Enalapril and Furosemide rx by rDVM

SPECIES
Canine
Abnormal PE/Chem/CBC/UA Results: CBC- Leukocytosis- WBC's 36.22 K/uL Neutrophilia 23.55 K/uL Lymphocytosis 5.21 K/uL Monocytosis 6.71 K/uL Chem- elevated BUN 28 mg/dL AFAST- appears to have fluid filled structure within abdomen suspect pyometra based on clinical signs and discharge, however it appears as though it may have different orientation than what I typically see seems to have multiple loops that are folded on top of each other.

BREED COMPUTED TOMOGRAPHIC STUDY OF THE THORAX & ABDOMEN

BREED
Chihuahua
Post-contrast studies available for review.

SEX COMPUTED TOMOGRAPHIC FINDINGS

SEX
FI
Limited study owing to the presence of multiple beam hardening streaks.

Abdomen

AGE
13 Years
Severe distension of the uterine body and both uterine horns with fluid attenuating material is seen. The uterus wall is stretched and presents thin.

No evidence of peritoneal effusion or fat stranding is seen.

INTERPRETED BY

Nele Eley, DVM
Dr. med. Vet. DipECVDI

Both kidneys are small in size with multiple mineral attenuating foci within the renal diverticuli and mildly irregular surface as well as weak and heterogeneous nephrogram.

Thorax

HOSPITAL NAME

HOSPITAL NAME
Wilvet Salem
Moderate tracheal collapse is seen.

There appears to be a diffuse bronchial lung pattern with peribronchial cuffing which, however, may be enhanced by the relatively low degree of pulmonary inflation and motion related artifacts.

REFERRING VET

REFERRING VET
Dr. Crystal Ebert

COMPUTED TOMOGRAPHIC DIAGNOSIS

- Pyometra.
- Bilateral chronic hypercalcemic nephritis.
- Suspect lower airway disease.
- Tracheal collapse.

INVOICE

INVOICE
49898

INTERPRETATION OF THE FINDINGS & FURTHER RECOMMENDATIONS

DATE

DATE
1-27-22

The CT study confirms the presence of a severely fluid filled and distended uterus compatible with pyometra. At this time, there is no evidence of peritoneal perforation. Note the presence of morphological changes of the kidneys that suggest potential for chronic nephritis and decreased renal function/excretion. Correlate with the laboratory values.



PATIENT

Quila Molina

Presence of lower airway inflammation or infectious bronchitis cannot be ruled out entirely. Correlate with the clinical signs. However, part of the findings may be caused by or enhanced by the technique.

SPECIES

Canine

BREED

Chihuahua

SEX

FI

AGE

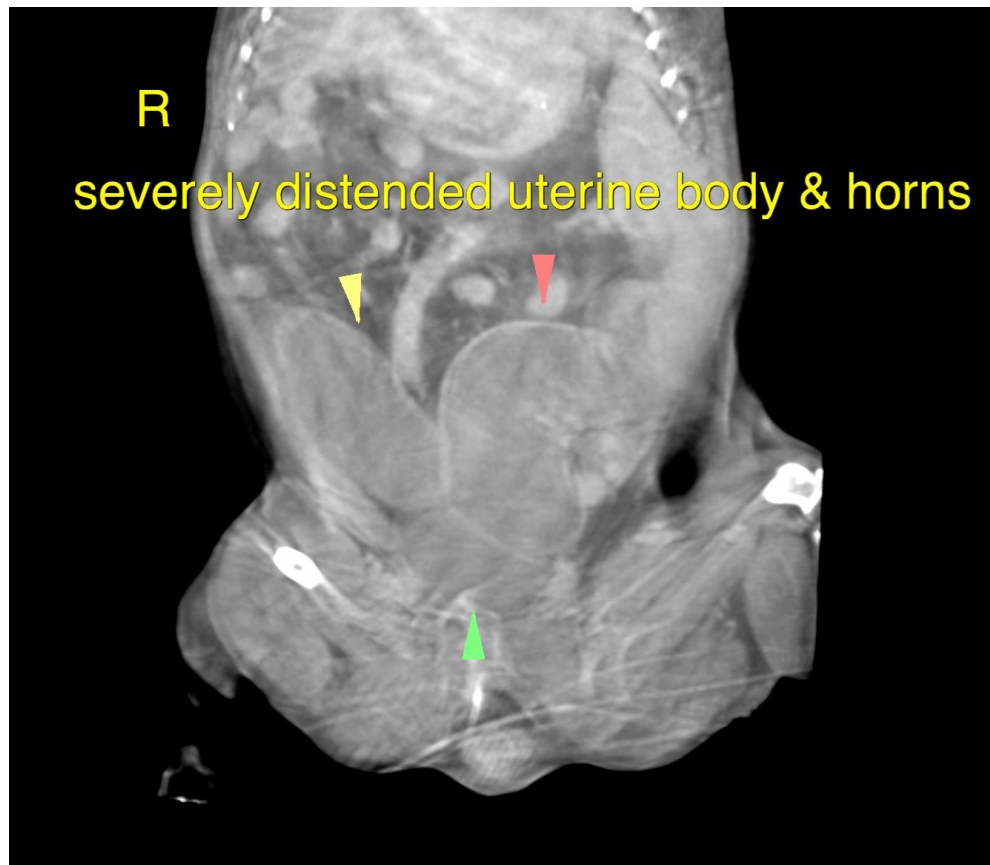
13 Years

INTERPRETED BY

Nele Eley, DVM
Dr. med. Vet. DipECVDI

HOSPITAL NAME

Wilvet Salem



REFERRING VET

Dr. Crystal Ebert

The information and recommendations provided are based on the images presented by the referring veterinarian/sonographer. No evaluation can be communicated regarding pathology that was not visible in the image/video clips provided.

Thank you for this referral. If the clinical or image interpretation does not parallel your findings or if I can be of any further assistance please contact me.

INVOICE

49898

Nele Eley, DVM, Dr. med. vet., DipECVDI
European Specialist in Veterinary Diagnostic Imaging, Cert. Radiology,
Senior lecturer University of Giessen, Germany, Veterinary Faculty, Department of Radiology
Nele.Eley@sonopath.com

DATE

1-27-22