



PATIENT

Mini Raungzeb

SPECIES

Canine

BREED

French Bulldog

SEX

Female

AGE

7Y, 3M

WEIGHT

9.1kg

INTERPRETED BY

Nele Eley (Ondreka),
DVM Dr. med. vet.,
DipECVDI

IMAGING PERFORMED BY

Ana

HOSPITAL NAME

Animal Trust - Bolton

REFERRING VET

Ana Valega

INVOICE

73443

DATE

1-26-26

PRESENTING CLINICAL SIGNS

History:

- Large mass started slowly developing since October 2024 - left hand side of vulva, ventral to anus - suspect 2 masses around 3cm each, previous FNAs - lipomas

Abnormal PE/Chem/CBC/UA Results: WNL

COMPUTED TOMOGRAPHIC STUDY OF THE ABDOMEN

Plain and post contrast studies are available for review.

COMPUTED TOMOGRAPHIC FINDINGS

A large well-defined fat attenuating mass measuring approximately 8 x 6 x 6 cm is seen in the perineal region caudal to the pelvis, to the left of the vulva and vaginal vestibule. The mass shows predominantly uniform fat attenuation consistent with adipose tissue. The mass margins are overall smooth with slight cranial irregularity at the interface with the perineal muscles. Mild displacement of the vulva vaginal vestibule and urethra are seen. No significant compression of the adjacent tissues is noted at the time of the examination. There is no evidence of osseous involvement or overt infiltrative behavior or the peripheral tissues.

The uterus and ovaries present within normal limits.

The serosal fat presents normal attenuation behavior. There is no evidence of peritoneal effusion or peritonitis.

Both kidneys present within normal limits for size, shape and organ architecture. After contrast administration, a bilaterally symmetric and uniform nephro- and pyelogram is noted.

The adrenal glands are within normal limits for size, shape and organ architecture.

Both liver and spleen present with normal shape, even surface, uniformly attenuating parenchyma and homogeneous contrast enhancement, unremarkable.

The pancreas is evenly contoured; the pancreatic parenchyma is homogeneous and presents uniform contrast enhancement.

The position, delineation, wall and content of the gastrointestinal tract are considered within normal limits throughout.

COMPUTED TOMOGRAPHIC DIAGNOSIS

- Large fat attenuating perineal mass consistent with lipoma.

INTERPRETATION OF FINDINGS & FURTHER RECOMMENDATIONS

The CT study reveals a large fat attenuating mass consistent with lipoma in the left perineal area. The slight cranial irregularity may reflect early fibrous septation or minor local reactive change. However, aggressive features such as tissue invasion are not overtly seen. The findings are not suggesting perineal hernia with fat protrusion. Liposarcoma and infiltrative lipoma can never be completely excluded but are considered by far less likely. Surgical excision can be considered if the mass causes



PATIENT

Mini Raungzeb

SPECIES

Canine

BREED

French Bulldog

SEX

Female

AGE

7Y, 3M

WEIGHT

9.1kg

INTERPRETED BY

Nele Eley (Ondreka),
DVM Dr. med. vet.,
DipECVDI

IMAGING PERFORMED BY

Ana

HOSPITAL NAME

Animal Trust - Bolton

REFERRING VET

Ana Valega

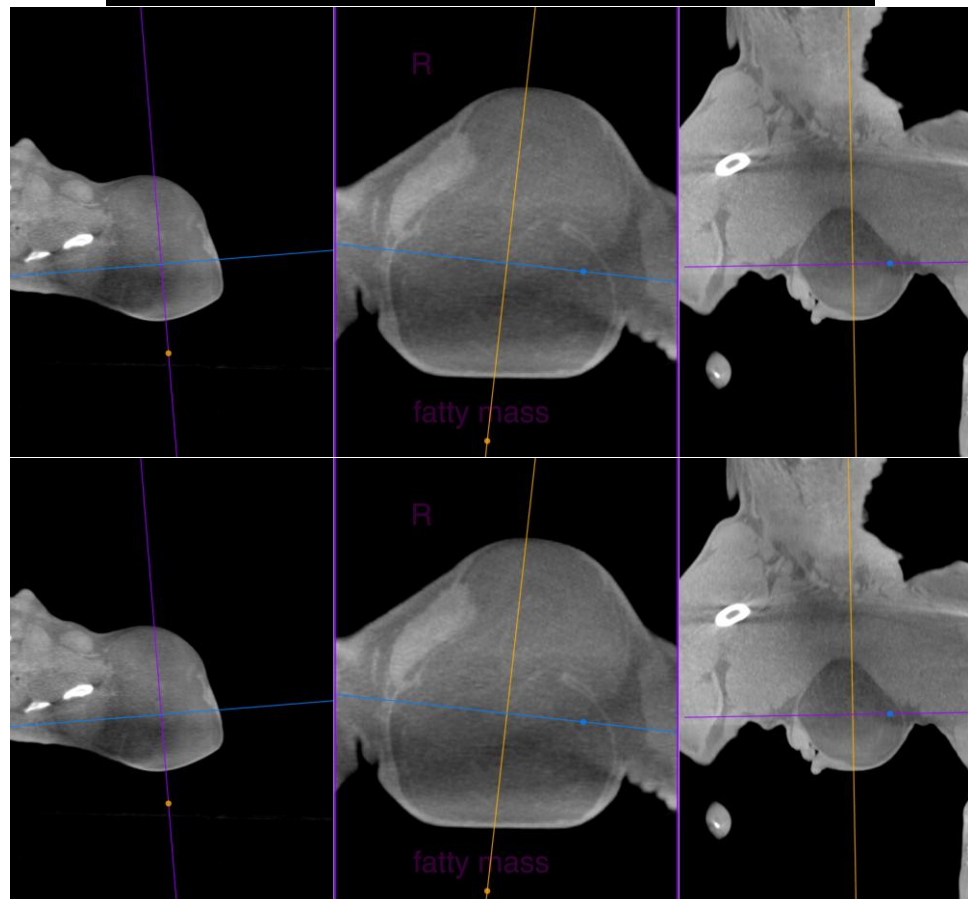
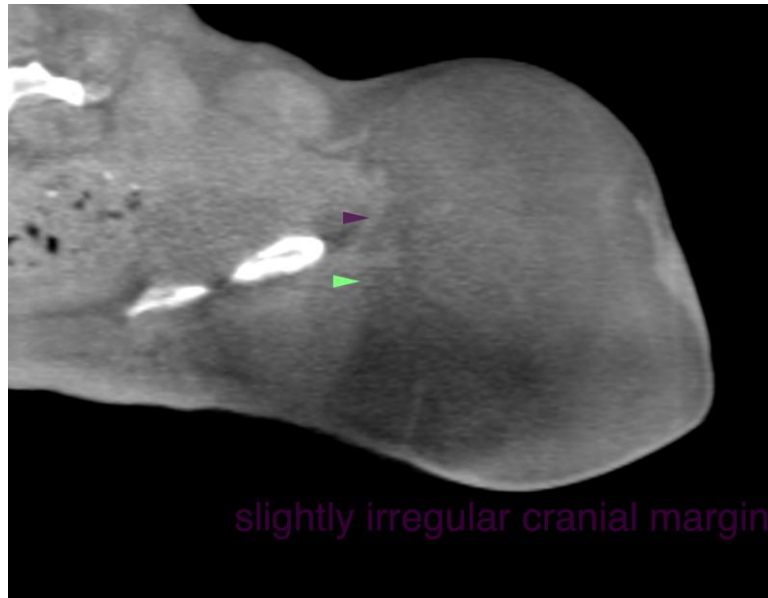
INVOICE

73443

DATE

1-26-26

discomfort or functional compromise. Histopathology is always recommended following excision to confirm benignity particularly given slight cranial irregularity.





PATIENT

Mini Raungzeb

SPECIES

Canine

BREED

French Bulldog

SEX

Female

AGE

7Y, 3M

WEIGHT

9.1kg

INTERPRETED BY

Nele Eley (Ondreka),
DVM Dr. med. vet.,
DipECVDI

IMAGING PERFORMED BY

Ana

HOSPITAL NAME

Animal Trust - Bolton

REFERRING VET

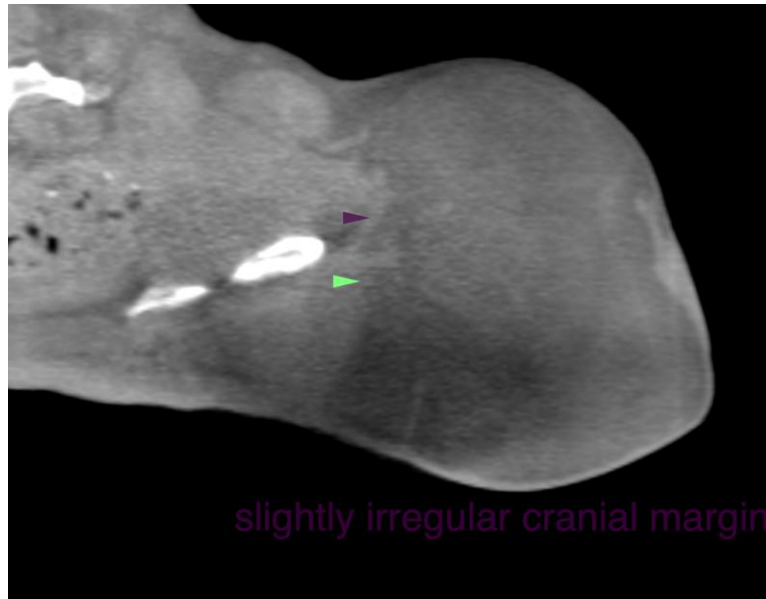
Ana Valega

INVOICE

73443

DATE

1-26-26



The information and recommendations provided are based on the images presented by the referring veterinarian. No evaluation can be communicated regarding pathology that was not visible in the image/video clips provided.

Thank you for this referral. If the clinical or image interpretation does not parallel your findings or if I can be of any further assistance please contact me.

Nele Eley (Ondreka), DVM, Dr. med. vet., DipECVDI
European Specialist in Veterinary Diagnostic Imaging, Cert. Radiology,
Senior lecturer University of Giessen/Germany, Veterinary Faculty, Department of Radiology.
info@sonopath.com