

**PATIENT**

Morgase Bartel

**PRESENTING CLINICAL SIGNS**

Right forelimb lameness began late September. Lameness was intermittent and unresponsive to cage rest. Suspect bilateral elbow dysplasia (FMCP), sub clinical in the LFL and clinic in the RFL.

**SPECIES**

Canine

**COMPUTED TOMOGRAPHIC STUDY OF THE ELBOWS**

Plain studies of the left and right elbow available for review.

**BREED**

Newfoundland

**COMPUTED TOMOGRAPHIC FINDINGS**

A 2.5 mm sized fragment is isolated from the severely heterogeneous tip of the left medial coronoid process. Extensive sclerosis of the coronoid base is seen. There is no evidence of defects in the medial humeral condyle. A mild amount of periarticular osteophytes is seen.

**SEX**

Female Intact

At least three fragments are isolated from the tip of the right medial coronoid process. Extensive sclerosis of the base of the medial coronoid process is seen. There is a 2mm sized subchondral bone defect within the medial humeral condyle surrounded by deep peripheral sclerosis. A moderate amount of periarticular osteophytes is present.

**AGE**

9 Months

**COMPUTED TOMOGRAPHIC DIAGNOSIS**

- Bilateral elbow dysplasia with fragmented medial coronoid processes.
- Osteochondritis of the medial humeral condyle of the right elbow.

**INTERPRETED BY**

Nele Eley, DVM  
Dr. med. Vet. DipECVDI

**INTERPRETATION OF THE FINDINGS & FURTHER RECOMMENDATIONS**

The CT study reveals osteochondritis of the medial humeral condyle in the right elbow as well as fragmentation of the medial coronoid process with at least three fragments. Moderate secondary osteoarthritic changes are seen.

**HOSPITAL NAME**

Bridgwater  
Veterinary Hospital  
and Wellness Centre

One fragment is isolated from the tip of the medial coronoid process in the left elbow. The left elbow joint reveals mild osteoarthritic changes.

The degree of osteoarthritic findings is remarkable in both joints considering the patient's age. Arthroscopic revision of both joints is recommended in order to remove the fragments, debride the subchondral bone defect, and prevent further damage to the articular structures.

**REFERRING VET**

Dr. Rentz

**INVOICE**

49862

**DATE**

1-26-22



**PATIENT**

Morgase Bartel

**SPECIES**

Canine

**BREED**

Newfoundland

**SEX**

Female Intact

**AGE**

9 Months

**INTERPRETED BY**

Nele Eley, DVM  
Dr. med. Vet. DipECVDI

**HOSPITAL NAME**

Bridgwater  
Veterinary Hospital  
and Wellness Centre

**REFERRING VET**

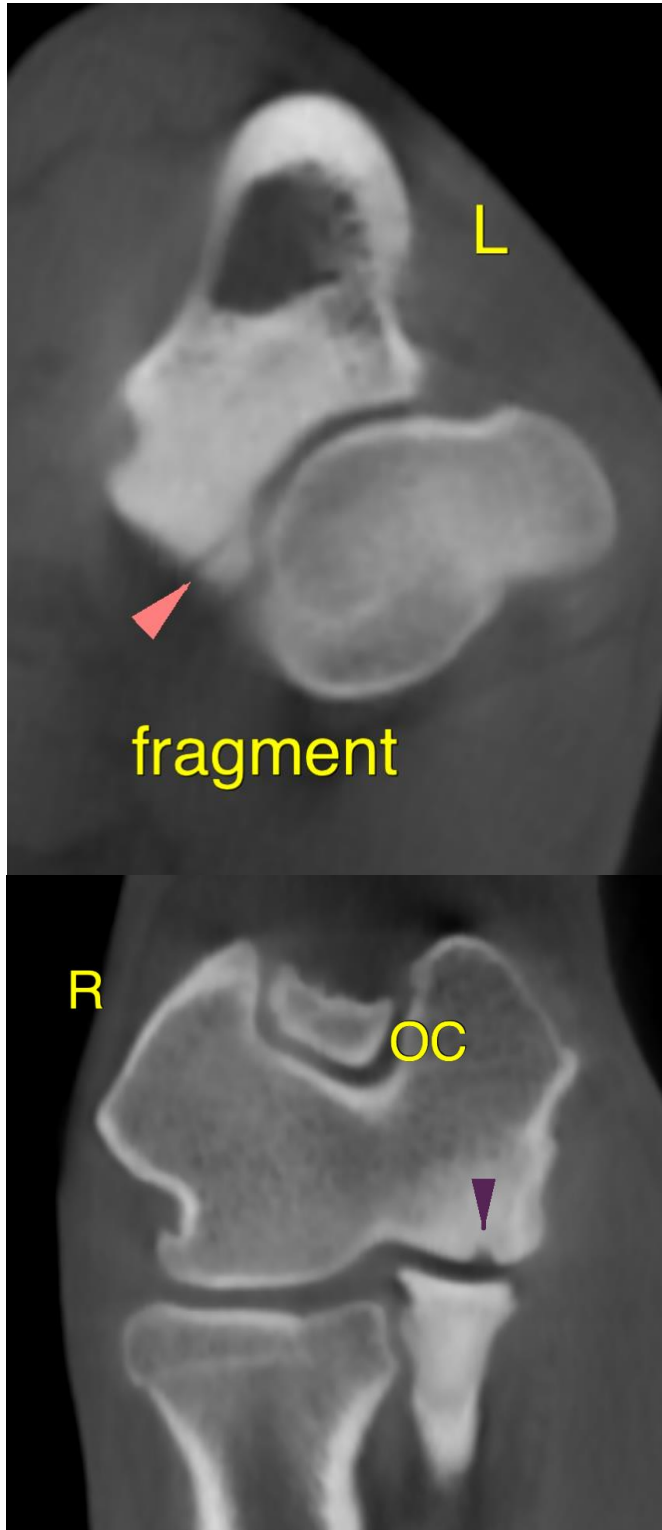
Dr. Rentz

**INVOICE**

49862

**DATE**

1-26-22





**PATIENT**

Morgase Bartel

**SPECIES**

Canine

**BREED**

Newfoundland

**SEX**

Female Intact

**AGE**

9 Months

**INTERPRETED BY**

Nele Eley, DVM  
Dr. med. Vet. DipECVDI

**HOSPITAL NAME**

Bridgwater  
Veterinary Hospital  
and Wellness Centre

**REFERRING VET**

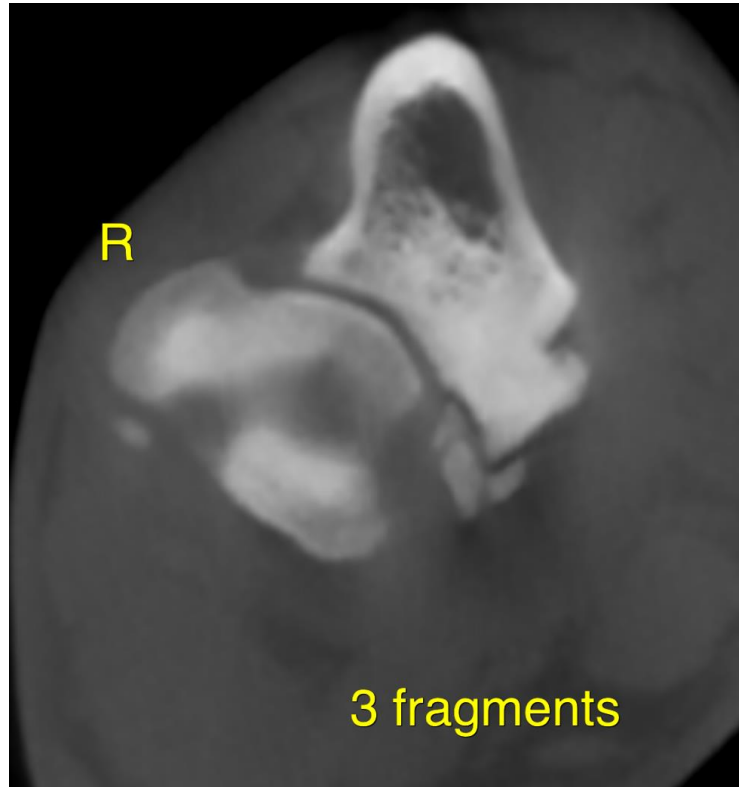
Dr. Rentz

**INVOICE**

49862

**DATE**

1-26-22



The information and recommendations provided are based on the images presented by the referring veterinarian/sonographer. No evaluation can be communicated regarding pathology that was not visible in the image/video clips provided.

Thank you for this referral. If the clinical or image interpretation does not parallel your findings or if I can be of any further assistance please contact me.

**Nele Eley**, DVM, Dr. med. vet., DipECVDI  
European Specialist in Veterinary Diagnostic Imaging, Cert. Radiology,  
Senior lecturer University of Giessen, Germany, Veterinary Faculty, Department of Radiology  
Nele.Eley@sonopath.com