

PATIENT PRESENTING CLINICAL SIGNS

Chloe Hyatt
 Chloe is still limping on the right rear leg. Kristina would like nails done and an ear cleaning. Chloe isn't on any joint supplements or pain medication. Chloe is non weight bearing and will occasionally use it. She slid on the kitchen tile around Christmas time last year, and she started limping on that right rear leg. She didn't have any limping before that time.

SPECIES
 Canine
 Abnormal PE/Chem/CBC/UA Results: DEBRIS AND INFLAMMATION IN RIGHT EAR PAIN TO EXTENSION OF RIGHT STIFLE/HIP

RADIOGRAPHIC STUDY OF THE STIFLES & PELVIS

BREED
 Mastiff Mix
 Mediolateral and craniocaudal views of the stifles and ventrodorsal and lateral views of the pelvis totaling 10 images available for review.

RADIOGRAPHIC FINDINGS

SEX
 Female
 Moderate joint space divergence is seen in the right coxofemoral joints with reduced femoral head coverage. The femoral head center is lateral of the dorsal acetabular rim. Lateralized subchondral bone sclerosis of the acetabulum is seen.

AGE
 1 Year, 3 Months
 Mild incongruity of the left coxofemoral joint space is seen as well, however, the changes appear to be more pronounced on the right side.
 Mild disuse atrophy of the right hind limb musculature is noted.

INTERPRETED BY
 Nele Eley, DVM
 Dr. med. Vet. DipECVDI
 Both stifle joints present within normal limits. There is no evidence of articular swelling, traumatic osseous injury, or tibial thrust.

RADIOGRAPHIC DIAGNOSIS

- Bilateral canine hip dysplasia - right more than left.
- Mild disuse atrophy of the right hind limb musculature.

HOSPITAL NAME

Elizabeth Animal Hospital

INTERPRETATION OF THE FINDINGS & FURTHER RECOMMENDATIONS

The radiographic study suggests presence of bilateral canine hip dysplasia. Mild to moderate dysplasia is seen on the right side and mild dysplasia appears to be evident on the left side. However, it has to be noted that the degree of muscle relaxation under sedation or anesthesia as well as the stress on the joints may be even more pronounced in stressed radiographs or situations.

REFERRING VET

Kim Allyn, DVM

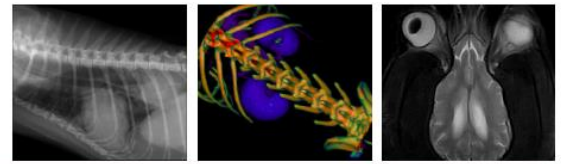
The radiographic presentation of the stifle joints was within normal limits.

INVOICE

49909

DATE

1-26-22



PATIENT

Chloe Hyatt

SPECIES

Canine

BREED

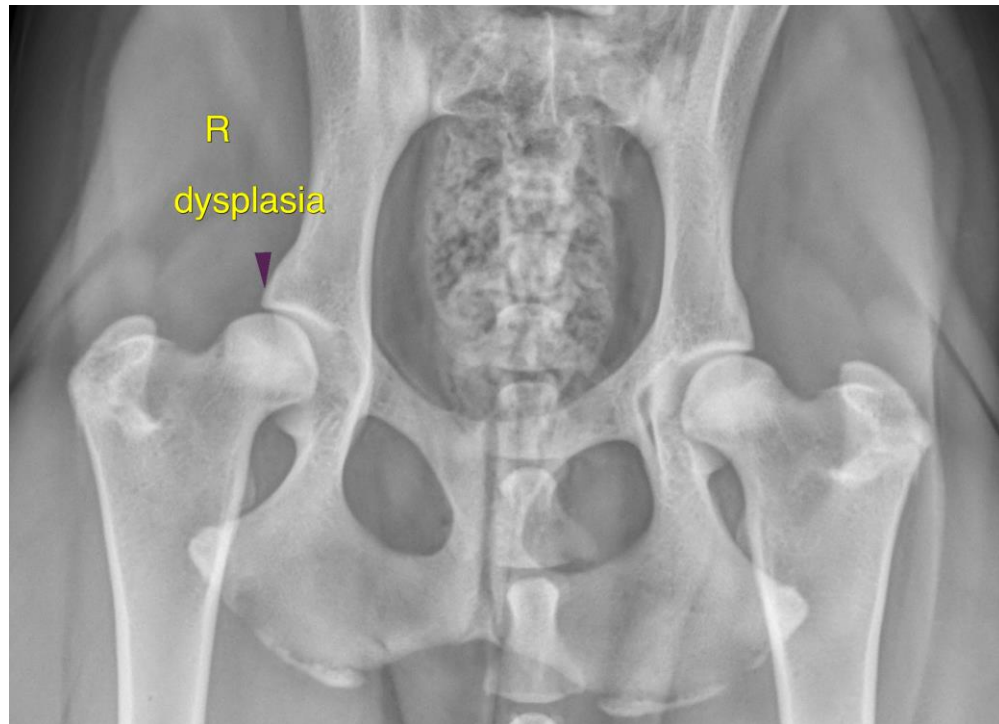
Mastiff Mix

SEX

Female

AGE

1 Year, 3 Months



INTERPRETED BY

Nele Eley, DVM
Dr. med. Vet. DipECVDI

The information and recommendations provided are based on the images presented by the referring veterinarian/sonographer. No evaluation can be communicated regarding pathology that was not visible in the image/video clips provided.

HOSPITAL NAME

Elizabeth Animal
Hospital

Thank you for this referral. If the clinical or image interpretation does not parallel your findings or if I can be of any further assistance please contact me.

Nele Eley, DVM, Dr. med. vet., DipECVDI
European Specialist in Veterinary Diagnostic Imaging, Cert. Radiology,
Senior lecturer University of Giessen, Germany, Veterinary Faculty, Department of Radiology
Nele.Eley@sonopath.com

REFERRING VET

Kim Allyn, DVM

INVOICE

49909

DATE

1-26-22