



**PATIENT PRESENTING CLINICAL SIGNS**

Kona Beaty coughing for three weeks and has serous nasal discharge. Per O her energy is lower. eating well, Owner called after being seen by a colleague who didn't find any issues and said cough is worse. I offered to see her and take rads and perform PCR and blood work, she declined. Treated with amoxi and baytril- no change

**SPECIES**

Canine

Abnormal PE/Chem/CBC/UA Results: mild serous nasal discharge and moist cough with exertion . T: 100.3 owner declined blood work, recommended Baerman- she is considering PCR upper resp being sent to Idexx

**BREED**

Husky

**RADIOGRAPHIC STUDY OF THE THORAX**

Right/left lateral and ventrodorsal views of the thorax totaling 3 images available for review.

**RADIOGRAPHIC FINDINGS**

**SEX**

FS

The degree of pulmonary inflation is deep. A moderate generalized bronchointerstitial lung pattern is noted and evenly distributed throughout the lung.

**AGE**

6 Years

The cardiac silhouette is upright and thin. The pulmonary vasculature and caudal vena cava are thin as well. The vertebral heart score is 9.3.

Course and width of the trachea are considered within normal limits.

There is no evidence of mediastinal lymphadenomegaly or other abnormal mediastinal widening.

The thoracic boundaries present within age related normal limits.

**INTERPRETED BY**

Nele Eley, DVM  
Dr. med. Vet. DipECVDI

**RADIOGRAPHIC DIAGNOSIS**

- Generalized bronchointerstitial lung pattern.
- Mild hypovolemia with microcardia and underperfusion of the lung.

**HOSPITAL NAME**

Northshore  
Veterinary Hospital

**INTERPRETATION OF THE FINDINGS & FURTHER RECOMMENDATIONS**

The radiographic study reveals a generalized bronchointerstitial lung pattern which suggests presence of lower airway disease such as infectious bronchitis including viral, bacterial, and parasitic as well as eosinophilic/allergic bronchopneumopathy. Allergic lower airway disease and parasitic bronchitis are thought to represent less likely differential diagnoses considering the concurrent presence of upper respiratory tract signs. However, final diagnosis would require sampling by means of endoscopy which should ideally include the upper and lower airways.

**REFERRING VET**

Brita Kiffney

**INVOICE**

56378

**DATE**

1-25-23



**PATIENT**

Kona Beaty

**SPECIES**

Canine

**BREED**

Husky

**SEX**

FS

**AGE**

6 Years

**INTERPRETED BY**

Nele Eley, DVM  
Dr. med. Vet. DipECVDI

**HOSPITAL NAME**

Northshore  
Veterinary Hospital

**REFERRING VET**

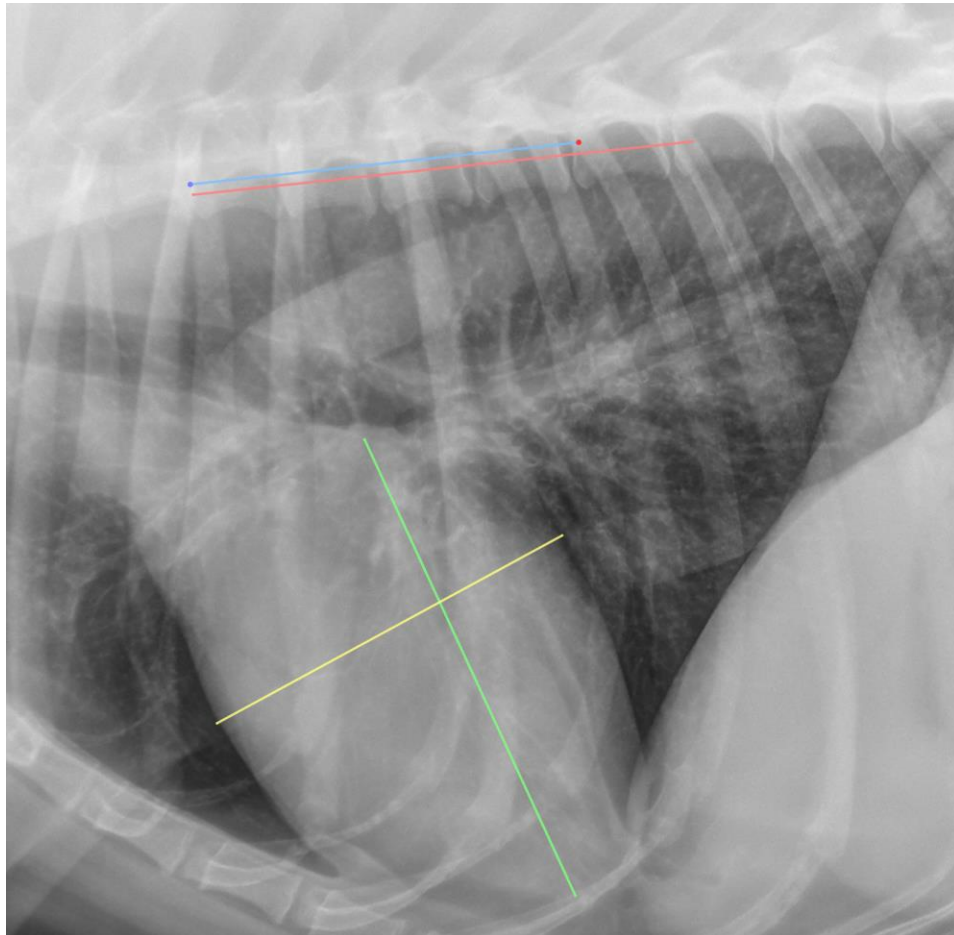
Brita Kiffney

**INVOICE**

56378

**DATE**

1-25-23



**The information and recommendations provided are based on the images presented by the referring veterinarian/sonographer. No evaluation can be communicated regarding pathology that was not visible in the image/video clips provided.**

Thank you for this referral. If the clinical or image interpretation does not parallel your findings or if I can be of any further assistance please contact me.

**Nele Eley, DVM, Dr. med. vet., DipECVDI**  
European Specialist in Veterinary Diagnostic Imaging, Cert. Radiology,  
Senior lecturer University of Giessen, Germany, Veterinary Faculty, Department of Radiology  
Nele.Eley@sonopath.com