



**PATIENT**

Rome Rose

**PRESENTING CLINICAL SIGNS**

2 weeks ago P had bloody diarrhea since has resolved, however, since P has had episodes of lip smacking and drooling at night  
Abnormal PE/Chem/CBC/UA Results: cbc, mini chem and UA pending

**SPECIES**

Canine

**RADIOGRAPHIC STUDY OF THE ABDOMEN**

Right/left lateral and ventrodorsal views totaling 3 images available for review.

**BREED**

Cane Corso

**RADIOGRAPHIC FINDINGS**

The surrounding bony structures are within normal limits.

**SEX**

Male Neutered

No abnormalities of the extraabdominal soft tissues are noted. The abdominal wall is smooth and thin.

The serosal detail is maintained throughout the peritoneal and retroperitoneal space.

The liver is appropriate in position, size and presents uniform opacity.

**AGE**

4.6 Years

The splenic head is in the anticipated position and within normal limits for size and opacity. The splenic body and tail are considered normal for position, size, shape and opacity.

Both kidneys are seen and present with normal size, shape, delineation and opacity. The urinary bladder is in its anticipated position. No radiopaque calculi are noted throughout the upper and lower urinary tract.

**INTERPRETED BY**

Nele Eley, DVM  
Dr. med. Vet. DipECVDI

Two metal clamps are seen in the region of the gastric outlet. A moderate amount of gas is present within the stomach.

**HOSPITAL NAME**

Boca Park Animal  
Hospital

The small intestinal loops reveal no evidence of plication or abnormal dilation.

The colon contains a mild amount of fecal matter.

**RADIOGRAPHIC DIAGNOSIS**

**REFERRING VET**

Laura Warren

- Small metal clamps in the region of the gastric outlet without radiographic evidence of ileus or peritonitis.

**INTERPRETATION OF THE FINDINGS & FURTHER RECOMMENDATIONS**

**INVOICE**

49833

The radiographic study reveals two metal clamps in the region of the gastric outlet which are very small and should be able to pass the gastrointestinal tract unless being attached to other nonradiopaque material. There is no evidence of intestinal plication, and no other signs of mechanical ileus are seen at this time. Consider gastroenteritis, pancreatopathy, and other potential differential diagnoses. Further workup by means of abdominal ultrasound could be considered in case of persisting clinical signs.

**DATE**

1-25-22



**PATIENT**

Rome Rose

**SPECIES**

Canine

**BREED**

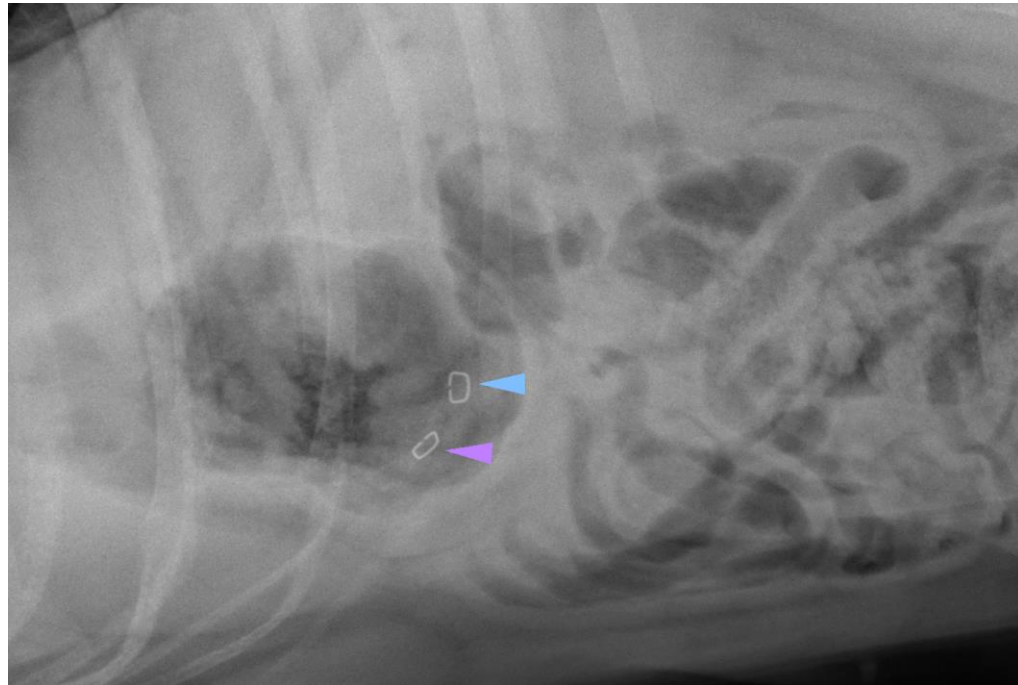
Cane Corso

**SEX**

Male Neutered

**AGE**

4.6 Years



**INTERPRETED BY**

Nele Eley, DVM  
Dr. med. Vet. DipECVDI

The information and recommendations provided are based on the images presented by the referring veterinarian/sonographer. No evaluation can be communicated regarding pathology that was not visible in the image/video clips provided.

Thank you for this referral. If the clinical or image interpretation does not parallel your findings or if I can be of any further assistance please contact me.

**HOSPITAL NAME**

Boca Park Animal  
Hospital

**Nele Eley**, DVM, Dr. med. vet., DipECVDI  
European Specialist in Veterinary Diagnostic Imaging, Cert. Radiology,  
Senior lecturer University of Giessen, Germany, Veterinary Faculty, Department of Radiology  
Nele.Eley@sonopath.com

**REFERRING VET**

Laura Warren

**INVOICE**

49833

**DATE**

1-25-22