



**PATIENT**

Kody Couto

**PRESENTING CLINICAL SIGNS**

Coughing since Christmas  
Abnormal PE/Chem/CBC/UA Results: mild elevation in BUN and Cr

**SPECIES**

Canine

**RADIOGRAPHIC STUDY OF THE THORAX**

Right/left lateral and ventrodorsal views totaling 3 images available for review.

**BREED**

American Eskimo

**RADIOGRAPHIC FINDINGS**

The patient appears to be obese.

The thoracic cavity presents a rather small volume.

**SEX**

Male Neuter

Marked cranial curvature of the diaphragmatic cupola is seen with an expanded ribcage which supports the presence of upper airway restriction.

Marked redundancy with in-folding of the dorsal tracheal ligament level with the caudal cervical trachea and thoracic inlet are seen.

**AGE**

12 Years

The lung presents a mild generalized bronchointerstitial pattern. Occasional pulmonary osteomas are seen which is considered within age related normal limits.

There is no radiographic evidence of cardiovascular pathology.

**INTERPRETED BY**

Nele Eley, DVM  
Dr. med. Vet. DipECVDI

No mediastinal widening is noted.

The abdominal cavity appears to be voluminous with liver margins extending beyond the costal arch.

**HOSPITAL NAME**

St. Catherine's Animal  
Hospital

**RADIOGRAPHIC DIAGNOSIS**

- Suspect upper airway restriction with dynamic tracheal disease.
- Normal age related lung and bronchial tree.
- No radiographic evidence of cardiovascular pathology.
- Obesity.
- Suspect hepatomegaly.

**REFERRING VET**

Dr. Mena

**INTERPRETATION OF THE FINDINGS & FURTHER RECOMMENDATIONS**

The radiographic findings suggest the presence of dynamic tracheal disease with reduced inflation of the lung secondary to upper airway restriction. Further evaluation of the upper and lower airways by means of endoscopy with airway sampling could be considered.

**INVOICE**

49831

**DATE**

1-25-22



**PATIENT**

Kody Couto

**SPECIES**

Canine

**BREED**

American Eskimo

**SEX**

Male Neuter

**AGE**

12 Years

**INTERPRETED BY**

Nele Eley, DVM  
Dr. med. Vet. DipECVDI

**HOSPITAL NAME**

St. Catherine's Animal  
Hospital

**REFERRING VET**

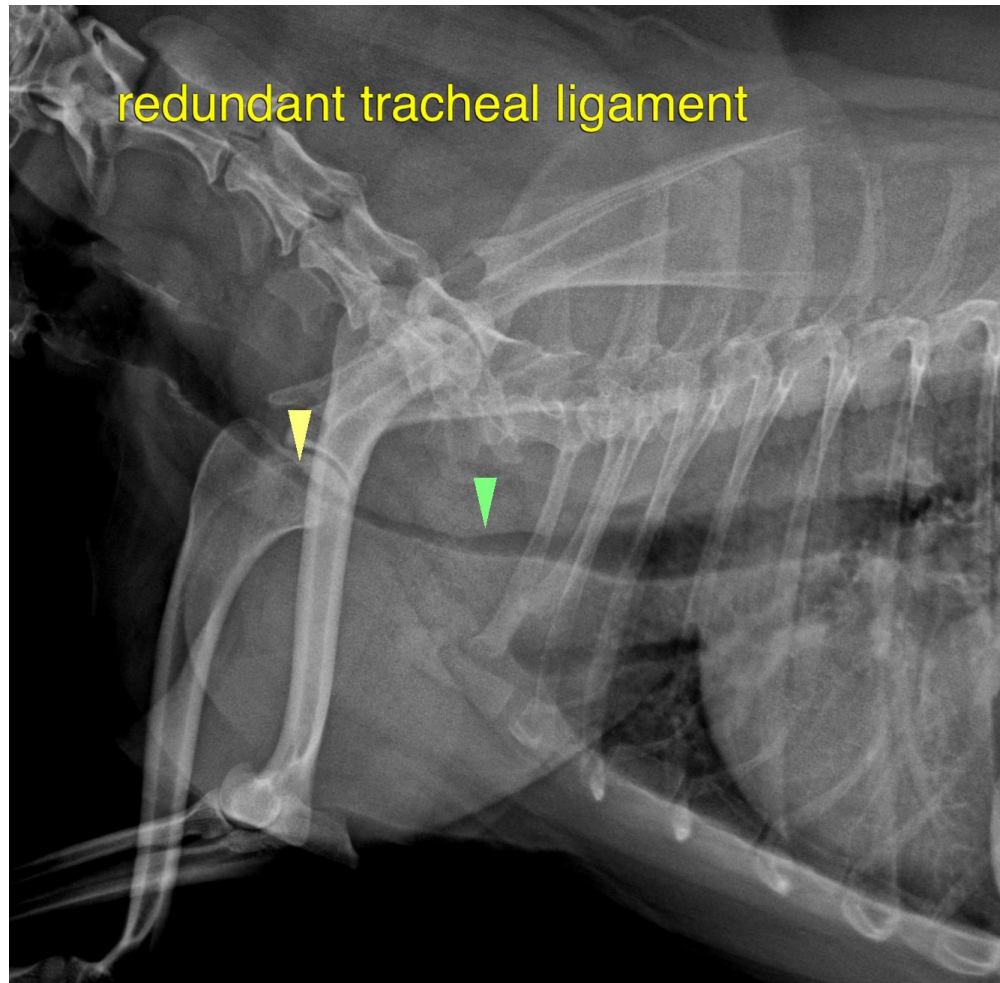
Dr. Mena

**INVOICE**

49831

**DATE**

1-25-22



The information and recommendations provided are based on the images presented by the referring veterinarian/sonographer. No evaluation can be communicated regarding pathology that was not visible in the image/video clips provided.

Thank you for this referral. If the clinical or image interpretation does not parallel your findings or if I can be of any further assistance please contact me.

**Nele Eley, DVM, Dr. med. vet., DipECVDI**  
European Specialist in Veterinary Diagnostic Imaging, Cert. Radiology,  
Senior lecturer University of Giessen, Germany, Veterinary Faculty, Department of Radiology  
Nele.Eley@sonopath.com