



PATIENT PRESENTING CLINICAL SIGNS

- Zeke Looney
- Chronic sneezing and nasal discharge (green or yellow)
 - Was previously on two courses of Doxycycline in which the symptoms never fully resolved
 - Progressing over the last week.
- SPECIES**
- Breathing rate appears relaxed at home with audible congestion, no open mouth breathing or distress noted.
- Feline
- AS is being held down but can visualize tympanic membranes bilaterally.

BREED COMPUTED TOMOGRAPHIC STUDY OF THE HEAD

DSH Plain and post contrast studies are available for review.

COMPUTED TOMOGRAPHIC FINDINGS

- SEX**
- MN Severe turbinate destruction with mucosal swelling is noted in the left nasal cavity. Early suspicion of dorsal cribriform plate lysis is noted.
- AGE**
- 10 Moderate multifocal mucosal swelling with milder turbinate destruction is present in the right nasal cavity and right frontal sinus which presents polypoid mucosal proliferations. Rightward deviation of the nasal septum is noted. Tissue accumulation and mild hyperostosis are noted in the presphenoidal sinus.

INTERPRETED BY

Nele Eley (Ondreka),
DVM Dr. med. vet.,
DipECVDI

Moderate left and mild right side tympanic bulla fluid accumulation are present. Tympanic membrane interruptions are suspected bilaterally.

Moderate bilateral retropharyngeal lymphadenomegaly is noted.

No overt intracranial masses or intracranial extension are detected.

HOSPITAL NAME

Southern Oregon
Veterinary Specialty

COMPUTED TOMOGRAPHIC DIAGNOSIS

- Severe destructive rhinitis, accentuating the left nasal cavity
- Moderate right sided rhinosinusitis
- Presphenoidal sinus involvement with tissue accumulation: suspect polyp
- Bilateral otitis media, left greater than right
- Suspect bilateral tympanic membrane rupture
- Bilateral retropharyngeal lymphadenopathy, likely reactive

REFERRING VET

Dr Applegate

INTERPRETATION OF FINDINGS & FURTHER RECOMMENDATIONS

INVOICE

23666

DATE

01/24/2026

The CT findings suggest chronic destructive rhinosinusitis with bilateral occurrence. The changes appear to be more advanced and more aggressive on the left side. Severe chronic fungal or bacterial rhinitis is a primary differential diagnosis given the turbinate destruction and early cribriform plate involvement. Secondary sinusitis with polyp, mucosal proliferations and bilateral otitis media are noted. Nasal neoplasia cannot be excluded completely but is considered by far less likely.

Consider rhinoscopy with sampling for culture and biopsy to confirm destructive rhinosinusitis and



PATIENT

Zeke Looney

rule out neoplasia. FNA of the retropharyngeal lymph nodes could be considered for further definition as well.

Consider otoscopic workup and monitor neurological status given the suspected early cribriform plate involvement on the left hand side.

SPECIES

Feline

BREED

DSH

SEX

MN

AGE

10

INTERPRETED BY

Nele Eley (Ondreka),
DVM Dr. med. vet.,
DipECVDI

HOSPITAL NAME

Southern Oregon
Veterinary Specialty

REFERRING VET

Dr Applegate

INVOICE

23666

DATE

01/24/2026



PATIENT

Zeke Looney

SPECIES

Feline

BREED

DSH

SEX

MN

AGE

10

INTERPRETED BY

Nele Eley (Ondreka),
DVM Dr. med. vet.,
DipECVDI

HOSPITAL NAME

Southern Oregon
Veterinary Specialty

REFERRING VET

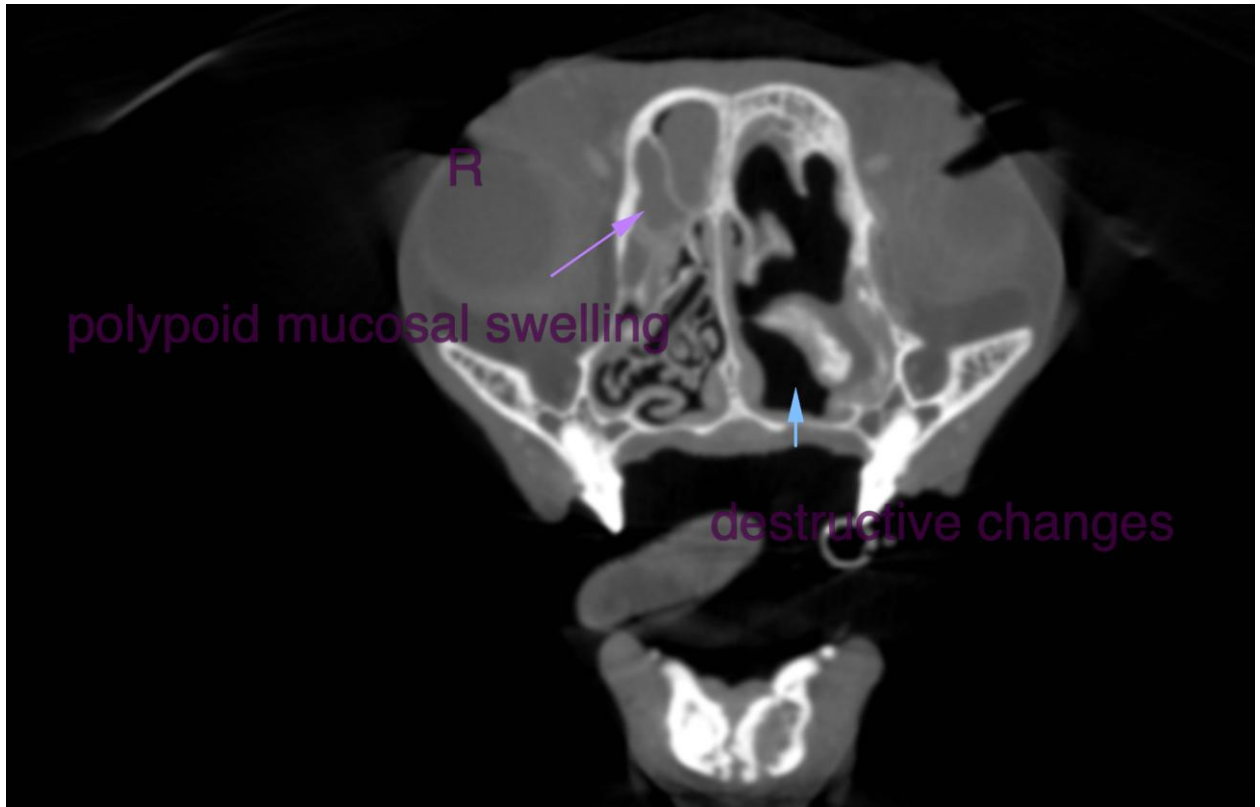
Dr Applegate

INVOICE

23666

DATE

01/24/2026





PATIENT

Zeke Looney

SPECIES

Feline

BREED

DSH

SEX

MN

AGE

10

INTERPRETED BY

Nele Eley (Ondreka),
DVM Dr. med. vet.,
DipECVDI

HOSPITAL NAME

Southern Oregon
Veterinary Specialty

REFERRING VET

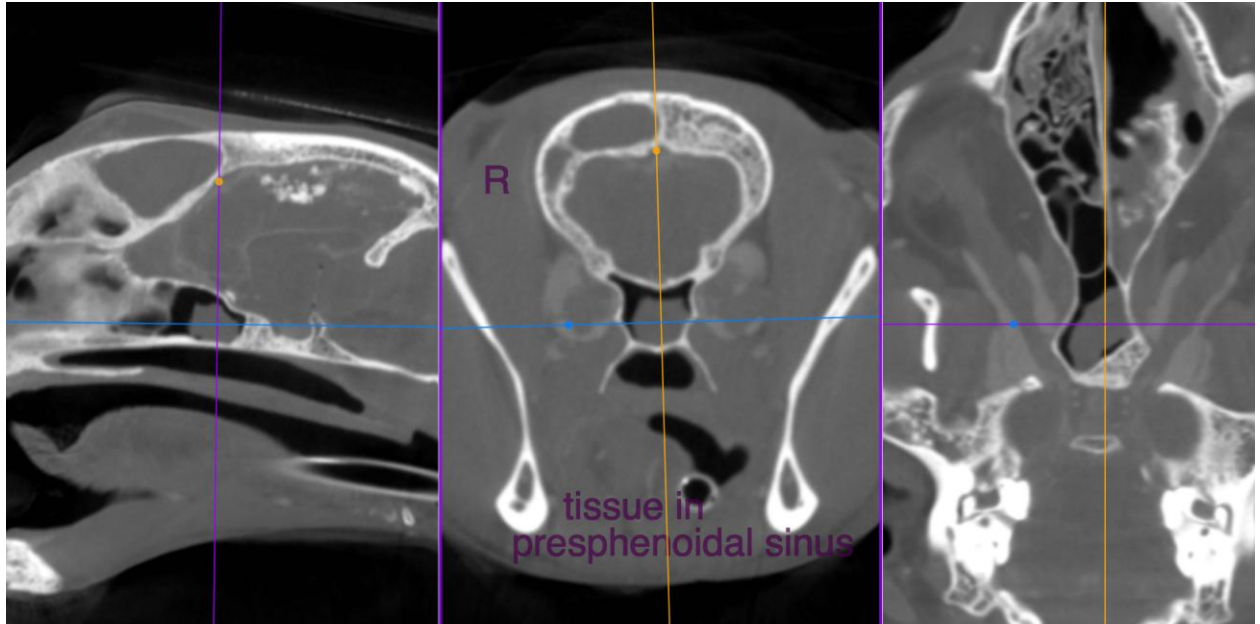
Dr Applegate

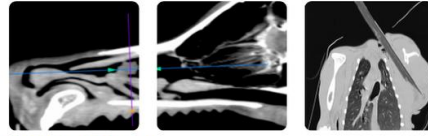
INVOICE

23666

DATE

01/24/2026





PATIENT

Zeke Looney

SPECIES

Feline

BREED

DSH

SEX

MN

AGE

10

INTERPRETED BY

Nele Eley (Ondreka),
DVM Dr. med. vet.,
DipECVDI

HOSPITAL NAME

Southern Oregon
Veterinary Specialty

REFERRING VET

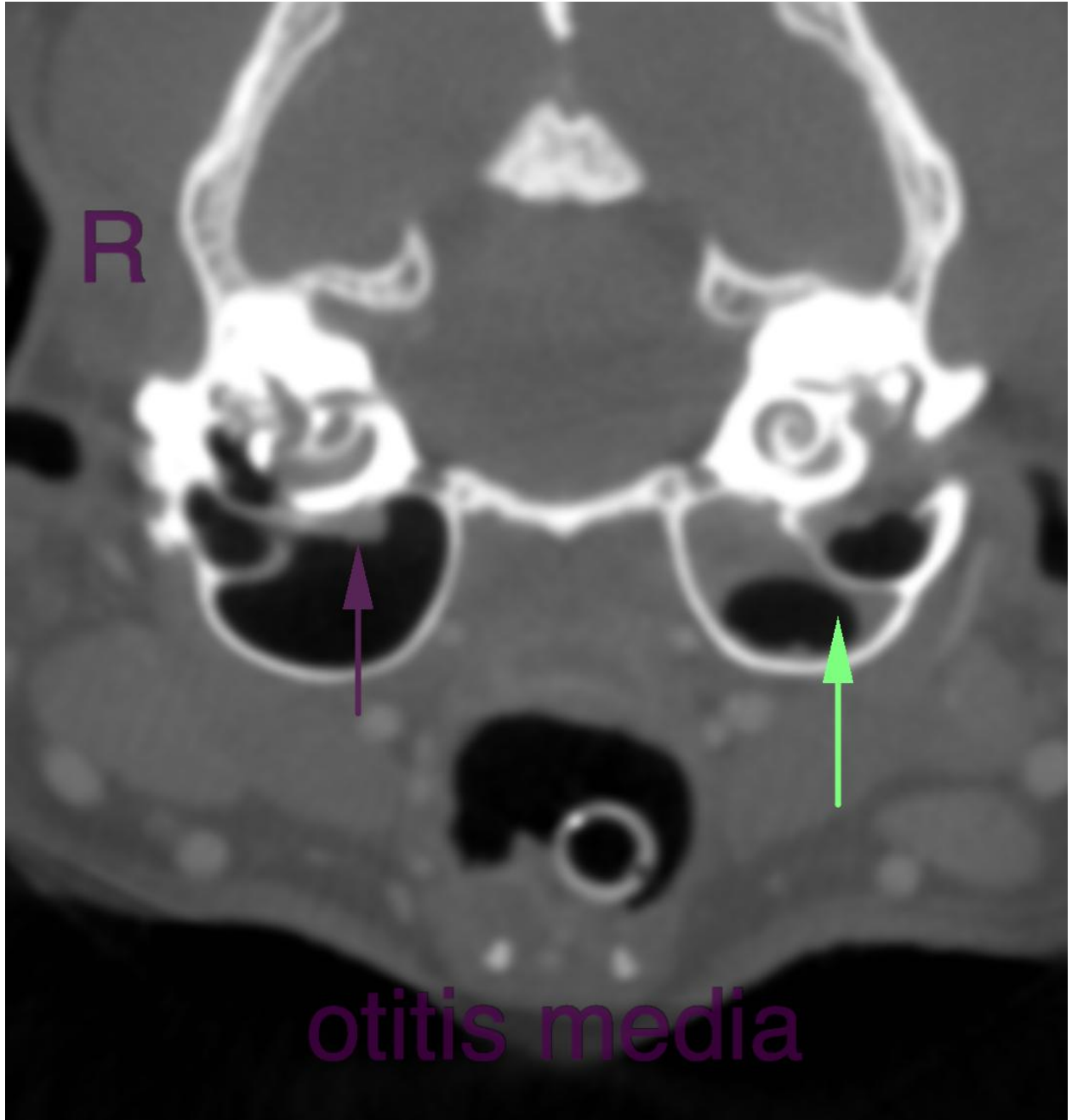
Dr Applegate

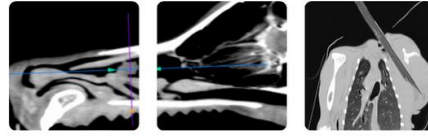
INVOICE

23666

DATE

01/24/2026





PATIENT

Zeke Looney

The information and recommendations provided are based on the images presented by the referring veterinarian. No evaluation can be communicated regarding pathology that was not visible in the image/video clips provided.

SPECIES

Feline

Thank you for this referral. If the clinical or image interpretation does not parallel your findings or if I can be of any further assistance please contact me.

BREED

DSH

Nele Eley (Ondreka), DVM, Dr. med. vet., DipECVDI
European Specialist in Veterinary Diagnostic Imaging, Cert. Radiology,
Senior lecturer University of Giessen/Germany, Veterinary Faculty, Department of Radiology.
info@sonopath.com

SEX

MN

AGE

10

INTERPRETED BY

Nele Eley (Ondreka),
DVM Dr. med. vet.,
DipECVDI

HOSPITAL NAME

Southern Oregon
Veterinary Specialty

REFERRING VET

Dr Applegate

INVOICE

23666

DATE

01/24/2026