



PATIENT

Pepper Blocker

PRESENTING CLINICAL SIGNS

Chronic right hind lameness, 2-3 months duration. Some improvement with NSAIDS and rest, but lameness returns with any activity. On PE - right stifle with moderate thickening and pain on extension. Mild laxity in stifle as well with manipulation.

SPECIES

Canine

RADIOGRAPHIC STUDY OF THE STIFLES

Mediolateral flexed views of both stifles and ventrodorsal hip extended view of the pelvis totaling 3 images available for review.

BREED

Blue Heeler

RADIOGRAPHIC FINDINGS

Moderate atrophy of the left hind limb muscles is noted.

SEX

The right stifle joint presents within normal limits.

MN

Moderate articular swelling of the left stifle joint with mild cranial thrust of the tibia is seen. There is a mild amount of periarticular osteophytes at the distal pole of the patella, femoral trochlea, and cranial margin of the tibial plateau.

AGE

3 Years, 8 Months

RADIOGRAPHIC DIAGNOSIS

- Mild left stifle osteoarthritis with radiographic signs of cruciate ligament injury.
- Disuse atrophy of the left hind limb musculature.

INTERPRETED BY

Nele Eley, DVM
Dr. med. Vet. DipECVDI

INTERPRETATION OF THE FINDINGS & FURTHER RECOMMENDATIONS

The radiographic study reveals left stifle osteoarthritis with evidence of cruciate ligament injury. The patient history reports lameness of the right hind limb. Clinical correlation is required here. There appears to be cruciate ligament injury such as partial or full rupture in the left stifle which may or may not be concurred by meniscal damage. Mild signs of osteoarthritis and moderate synovitis/effusion is seen. Surgical intervention could be considered for the left stifle in case this is the actual cause of the patient's clinical signs in order to address the presumed loss of biomechanical stability and prevent further damage to the articular structures.

HOSPITAL NAME

Gentle Doctor Animal
Hospital

REFERRING VET

Megan Belfiore

INVOICE

56370

DATE

1-24-23



PATIENT

Pepper Blocker

SPECIES

Canine

BREED

Blue Heeler

SEX

MN

AGE

3 Years, 8 Months

INTERPRETED BY

Nele Eley, DVM
Dr. med. Vet. DipECVDI

HOSPITAL NAME

Gentle Doctor Animal
Hospital

REFERRING VET

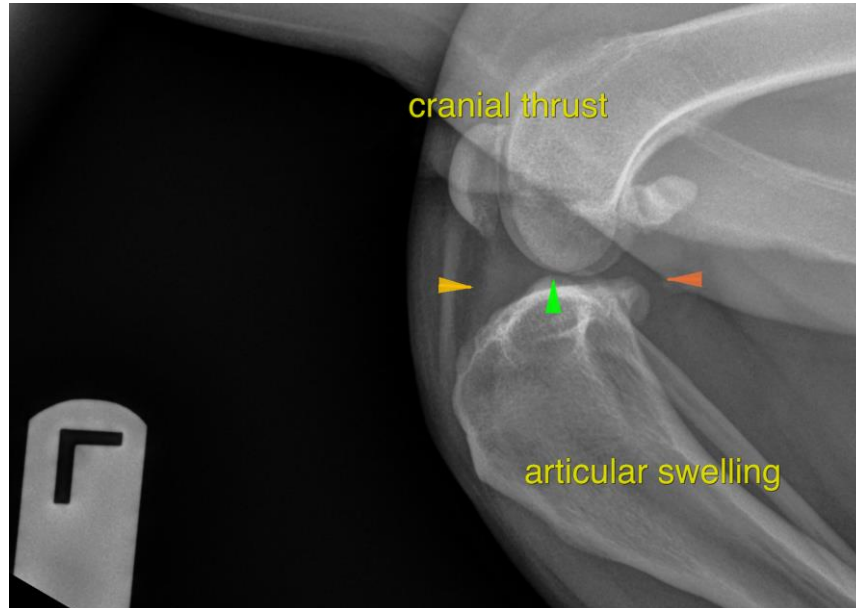
Megan Belfiore

INVOICE

56370

DATE

1-24-23



The information and recommendations provided are based on the images presented by the referring veterinarian/sonographer. No evaluation can be communicated regarding pathology that was not visible in the image/video clips provided.

Thank you for this referral. If the clinical or image interpretation does not parallel your findings or if I can be of any further assistance please contact me.

Nele Eley, DVM, Dr. med. vet., DipECVDI
European Specialist in Veterinary Diagnostic Imaging, Cert. Radiology,
Senior lecturer University of Giessen, Germany, Veterinary Faculty, Department of Radiology
Nele.Eley@sonopath.com