



PATIENT PRESENTING CLINICAL SIGNS

Willow Evans P first presented on 12/23/21 for toe touching lameness on RH. No diagnostics done at that time, P started on Rimadyl. P has not improved since. On exam, stifles both palpated normal, negative drawer/thrust. R hip extremely stiff, unable to extend even with P under full sedation.

SPECIES RADIOGRAPHIC STUDY OF THE PELVIS & THORAX

Canine Ventrodorsal hip extended view of the pelvis, mediolateral faux profile view of the right femur, mediolateral views of the left and right stifle, right left lateral and ventrodorsal views of the thorax totaling 8 images available for review.

BREED Golden Retriever Thoracic and pelvic read requested.

RADIOGRAPHIC FINDINGS

SEX Pelvis

SF The muscle volume of the right hind limb is reduced.

AGE An intermuscular lipoma is seen in the right caudoproximal thigh.

10 Years There is a monostotic aggressive osteolytic lesion within the right proximal femur presenting permeative lysis with long and indistinct transition zones within the proximal diaphyseal third and proximal metaphysis of the femur. Amorphous and laminar periosteal new bone is seen. There is multifocal endosteal scalloping with cortical bone thinning noted.

INTERPRETED BY

Nele Eley, DVM
Dr. med. Vet. DipECVDI

The coxofemoral joints present within age related normal limits.

Thorax

HOSPITAL NAME Multiple mild to moderate spondyloses are seen within the thoracic spine.

Grove Veterinary Clinic The extrathoracic soft tissues present homogeneous without abnormalities.

The heart is of normal size and shape and there is no evidence of cardiac chamber or vascular enlargement. The pulmonary vasculature is within normal limits.

REFERRING VET

Dr. Pospicahal The cranial mediastinum presents the expected soft tissue opacity. The mediastinal width is less than twice the width of the vertebral column at the same level.

INVOICE The trachea is normal in diameter and presents the anticipated course. The luminal outline of the trachea is smooth.

49812 The bronchial tree presents with thin walls and tapers uniformly towards the periphery as expected.

DATE The lung parenchyma presents the expected architecture and opacity. The intrapulmonary vascular branching is seen up to the third order lung vessels.

1-24-22 The diaphragm is well delineated with even surface and the expected mild cranial bulging of the



PATIENT diaphragmatic cupola.

Willow Evans

RADIOGRAPHIC DIAGNOSIS

SPECIES

Canine

- Monostotic aggressive osteolytic lesion of the right proximal femur.
- Disuse atrophy of the right hind limb musculature.
- Intermuscular lipoma in the right proximal thigh.
- No radiographic evidence of pulmonary metastatic disease.

BREED

Golden Retriever

INTERPRETATION OF THE FINDINGS & FURTHER RECOMMENDATIONS

The radiographic findings are highly suggestive for primary neoplasia of bone within the right proximal femur. Osteosarcoma is considered most likely. Chondrosarcoma and other primary neoplasia of bone as well as metastatic disease of another primary tumor cannot be ruled out entirely. Final diagnosis would require sampling for histology by means of bone biopsy.

SEX

SF

At this time, the radiographic screening for pulmonary metastatic disease was negative.

AGE

10 Years

INTERPRETED BY

Nele Eley, DVM
Dr. med. Vet. DipECVDI

HOSPITAL NAME

Grove Veterinary
Clinic

REFERRING VET

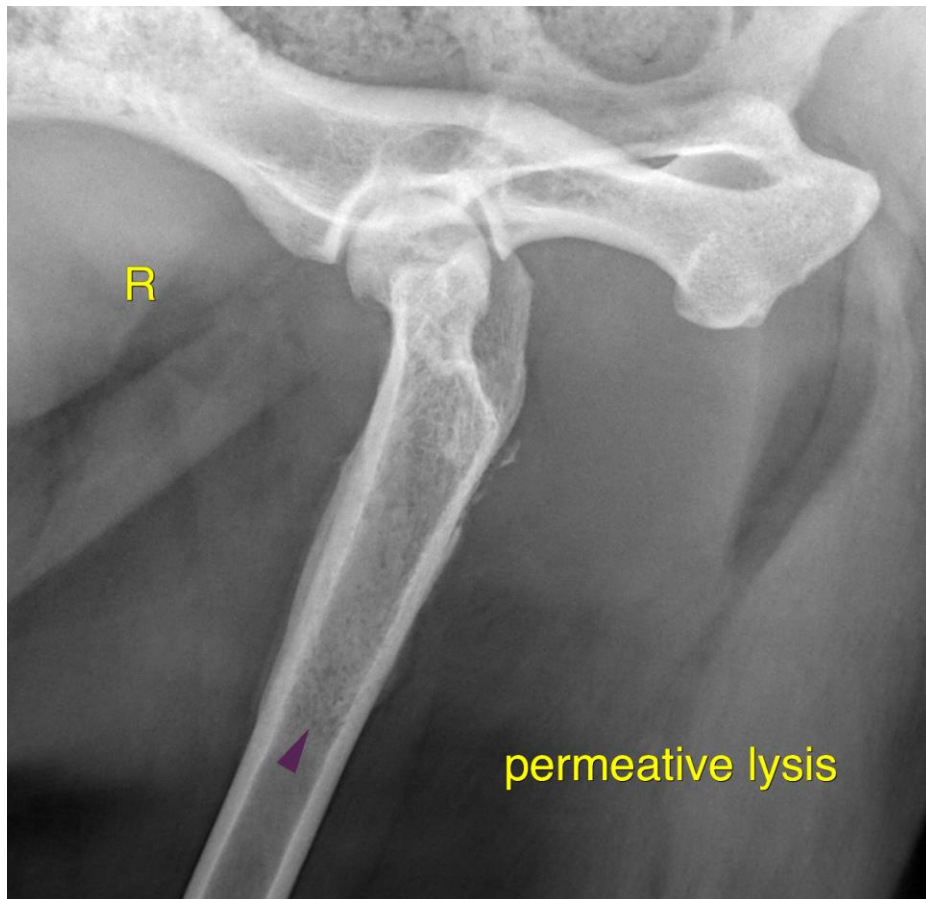
Dr. Pospicahal

INVOICE

49812

DATE

1-24-22





PATIENT

Willow Evans

The information and recommendations provided are based on the images presented by the referring veterinarian/sonographer. No evaluation can be communicated regarding pathology that was not visible in the image/video clips provided.

Thank you for this referral. If the clinical or image interpretation does not parallel your findings or if I can be of any further assistance please contact me.

SPECIES

Canine

Nele Eley, DVM, Dr. med. vet., DipECVDI
European Specialist in Veterinary Diagnostic Imaging, Cert. Radiology,
Senior lecturer University of Giessen, Germany, Veterinary Faculty, Department of Radiology
Nele.Eley@sonopath.com

BREED

Golden Retriever

SEX

SF

AGE

10 Years

INTERPRETED BY

Nele Eley, DVM
Dr. med. Vet. DipECVDI

HOSPITAL NAME

Grove Veterinary
Clinic

REFERRING VET

Dr. Pospicahal

INVOICE

49812

DATE

1-24-22