



## PATIENT PRESENTING CLINICAL SIGNS

Briar Calderon

- 2 yr old FS DSHA, recurring ear infections noted. Today having dental we noticed otitis media? AS. On videoscope the tympanum appears ruptured.

## SPECIES

Feline

## COMPUTED TOMOGRAPHIC STUDY OF THE HEAD

Plain study available for review only.

## BREED

DSH

## COMPUTED TOMOGRAPHIC FINDINGS

Moderate fluid accumulation with meniscus sign is seen in the right tympanic bulla with mild thickening of the osseous lining. The tympanic membrane is not seen.

## SEX

FS

The left bulla is completely fluid filled with moderate thickening of the osseous lining. The tympanic membrane is not seen.

## AGE

2yr

No polyps are identified in bulla, ear canals, or nasal pharynx. Overt evidence of intracranial extension is not noted. No inner ear structural abnormalities are seen.

The epithelial lining of the ear canals is thickened bilaterally with mild hypoattenuating material in the lumen of the ear canals.

## INTERPRETED BY

Nele Eley (Ondreka),  
DVM Dr. med. vet.,  
DipECVDI

## COMPUTED TOMOGRAPHIC DIAGNOSIS

- Chronic bilateral otitis media- left more advanced than right.
- Bilateral otitis externa.
- No polyps or intracranial extension seen.

## HOSPITAL NAME

Tenafly Vet Center

## INTERPRETATION OF FINDINGS & FURTHER RECOMMENDATIONS

The CT findings are consistent with chronic bilateral otitis media. The changes are bilateral yet more advanced based on the more severe osseous changes on the left hand side. Both tympanic membranes appear to be interrupted. Signs of bilateral otitis externa are seen. No evidence of tympanokeratoma formation, mass lesions, polyps, inner ear changes, or intracranial extension is noted.

## REFERRING VET

Dr Salas

Continuation of medical management could be considered with initiation of appropriate antibiotics and anti-inflammatory therapy targeting middle and external ear infections. Follow-up imaging could be considered to ensure resolution of bulla fluid. Ventral bulla osteotomy could be considered if recurrent or chronic otitis media does not respond to medical management.

## INVOICE

23663

## DATE

01/23/2026



## PATIENT

Briar Calderon

## SPECIES

Feline

## BREED

DSH

## SEX

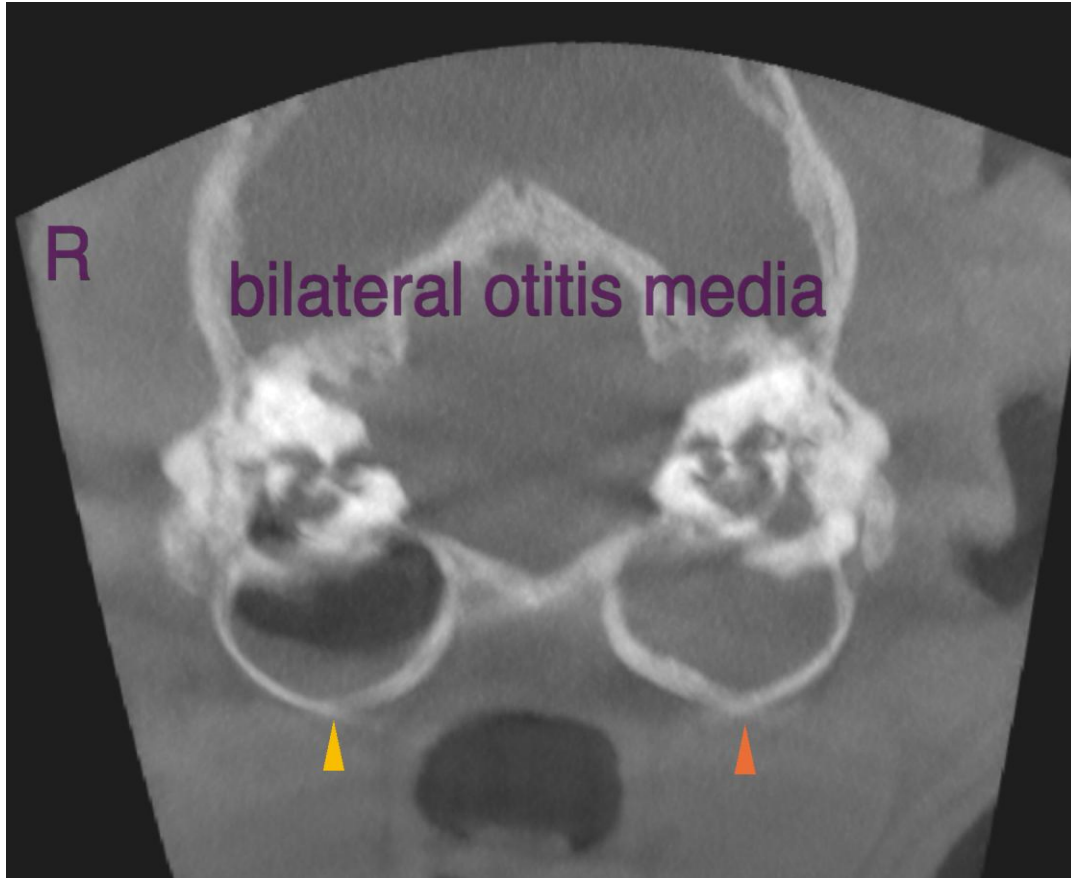
FS

## AGE

2yr

## INTERPRETED BY

Nele Eley (Ondreka),  
DVM Dr. med. vet.,  
DipECVDI



The information and recommendations provided are based on the images presented by the referring veterinarian. No evaluation can be communicated regarding pathology that was not visible in the image/video clips provided.

## HOSPITAL NAME

Tenafly Vet Center

Thank you for this referral. If the clinical or image interpretation does not parallel your findings or if I can be of any further assistance please contact me.

## REFERRING VET

Dr Salas

Nele Eley (Ondreka), DVM, Dr. med. vet., DipECVDI  
European Specialist in Veterinary Diagnostic Imaging, Cert. Radiology,  
Senior lecturer University of Giessen/Germany, Veterinary Faculty, Department of Radiology.  
[info@sonopath.com](mailto:info@sonopath.com)

## INVOICE

23663

## DATE

01/23/2026



## PATIENT

Briar Calderon

## SPECIES

Feline

## BREED

DSH

## SEX

FS

## AGE

2yr

## INTERPRETED BY

Nele Eley (Ondreka),  
DVM Dr. med. vet.,  
DipECVDI

## HOSPITAL NAME

Tenafly Vet Center

## REFERRING VET

Dr Salas

## INVOICE

23663

## DATE

01/23/2026