



PATIENT

Survivor Morales

PRESENTING CLINICAL SIGNS

O noted blood in urine on Saturday and p straining to defecate. Per o stool still normal. No v/d/c/s. Not eating well but drinking ok.
 Abnormal PE/Chem/CBC/UA Results: On rectal - normal stool, prostate enlarged on the right, bw and u/a pending, blood noted in urine

SPECIES

Canine

RADIOGRAPHIC STUDY OF THE ABDOMEN

Right/left lateral and ventrodorsal views totaling 3 images available for review.

BREED

Min Pin

RADIOGRAPHIC FINDINGS

The intervertebral disc space L1/2 presents severe asymmetric collapse with vertebral end plate sclerosis and lateral as well as ventral spondylosis deformans. Mineralized disc material can be seen in the ventral aspect of the vertebral canal.

SEX

Male

The patient is in thin body condition.

AGE

13 Years

Moderate enlargement of the prostate is seen. The prostatic index is 66% with reference to the pelvic inlet. See image below. No evidence of regional fat stranding or mineralization is seen.

The urinary bladder is empty. No abnormal opacities are seen superimposed onto the urinary bladder.

INTERPRETED BY

Nele Eley, DVM
 Dr. med. Vet. DipECVDI

No abnormal opacities are seen throughout the pathway of the membranous and penile urethra.

There is no radiographic evidence of sublumbar lymphadenomegaly.

RADIOGRAPHIC DIAGNOSIS

- Prostatomegaly
- Chronic intervertebral disc disease with mineralized disc hernia L1/2.

HOSPITAL NAME

The Pet Hospital of Stratford

INTERPRETATION OF THE FINDINGS & FURTHER RECOMMENDATIONS

The moderate enlargement of the prostate may reflect uncomplicated benign hyperplasia of the non-neutered male. Prostatitis and prostatic neoplasia as well as paraprostatic cyst are potential differential diagnoses. Further definition by means of abdominal ultrasound with eventual sampling could be considered and should include assessment of the genital as well as the lower urinary tract or full abdomen.

REFERRING VET

Dr. Claudia Giuliani, DVM

No evidence of sublumbar lymphadenomegaly was found radiographically. However, ultrasound offers greater sensitivity to detect early lymphadenopathy.

INVOICE

56314

There was no evidence of aggressive osteolytic changes in the lumbar spine. However, chronic and potentially compressive disc hernia appears to be present between L1 and L2 within the cranial lumbar spine.

DATE

1-23-23



PATIENT

Survivor Morales

SPECIES

Canine

BREED

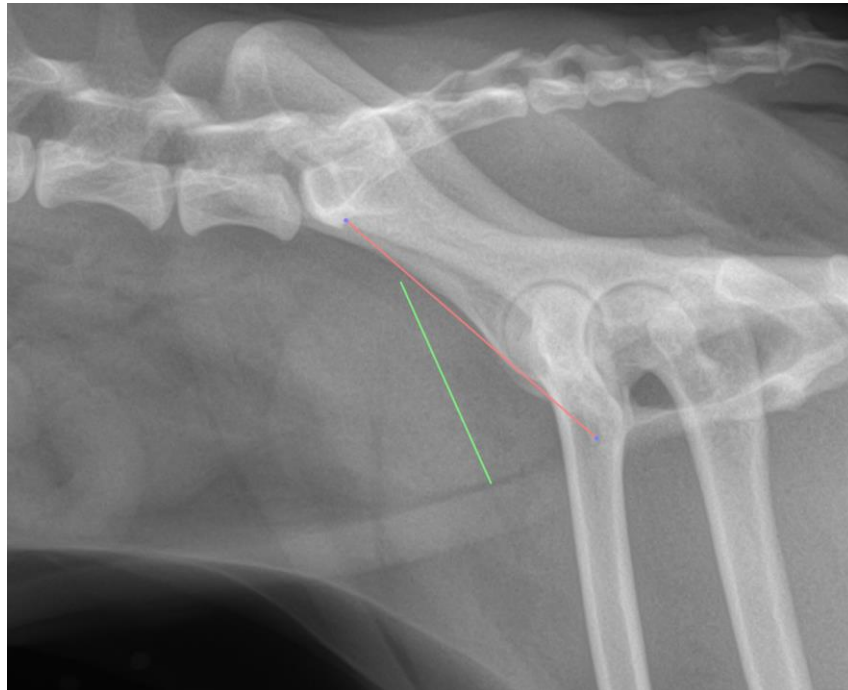
Min Pin

SEX

Male

AGE

13 Years



INTERPRETED BY

Nele Eley, DVM
Dr. med. Vet. DipECVDI

The information and recommendations provided are based on the images presented by the referring veterinarian/sonographer. No evaluation can be communicated regarding pathology that was not visible in the image/video clips provided.

Thank you for this referral. If the clinical or image interpretation does not parallel your findings or if I can be of any further assistance please contact me.

HOSPITAL NAME

The Pet Hospital of
Stratford

Nele Eley, DVM, Dr. med. vet., DipECVDI
European Specialist in Veterinary Diagnostic Imaging, Cert. Radiology,
Senior lecturer University of Giessen, Germany, Veterinary Faculty, Department of Radiology
Nele.Eley@sonopath.com

REFERRING VET

Dr. Claudia Giuliani,
DVM

INVOICE

56314

DATE

1-23-23