



PATIENT

Enzo Estua

PRESENTING CLINICAL SIGNS

inappetence x4 days; febrile
Abnormal PE/Chem/CBC/UA Results: labs pending

SPECIES

Canine

RADIOGRAPHIC STUDY OF THE ABDOMEN

Right lateral and ventrodorsal views of the abdomen totaling 2 images available for review.

BREED

Goldendoodle

RADIOGRAPHIC FINDINGS

The abdominal serosal detail is maintained.

Mild gastric aerophagia is noted.

SEX

Male Neutered

The small intestinal loops are evenly distributed throughout the mid abdomen without evidence of abnormal dilation, plication, or radiopaque foreign material.

A moderate amount of fecal matter is seen within the large intestine. The cecum and transverse colon appear to contain gas.

AGE

2 Years

The splenic tail and liver present within normal limits.

The assessment of the kidneys is limited due to the superimposition with the gastrointestinal tract. No structural abnormalities of the kidneys are noted.

INTERPRETED BY

Nele Eley, DVM
Dr. med. Vet. DipECVDI

RADIOGRAPHIC DIAGNOSIS

- Gastrointestinal aerophagia – otherwise normal presentation of the abdomen.

HOSPITAL NAME

New Bridge
Veterinary Practice

INTERPRETATION OF THE FINDINGS & FURTHER RECOMMENDATIONS

The radiographic presentation of the abdomen is considered within normal limits. Mild gastrointestinal aerophagia is noted and may be due to gastroenteropathy, stress, or pain, and less likely respiratory distress. Full internal medicine workup could be considered if not performed already.

REFERRING VET

Dr. Abina Glennon

INVOICE

56319

DATE

1-23-23



PATIENT

Enzo Estua

SPECIES

Canine

BREED

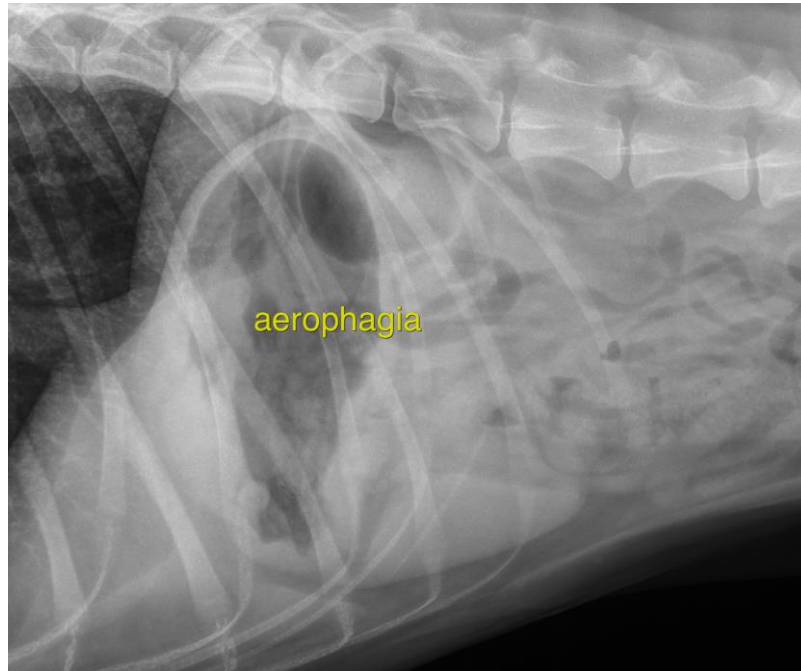
Goldendoodle

SEX

Male Neutered

AGE

2 Years



INTERPRETED BY

Nele Eley, DVM
Dr. med. Vet. DipECVDI

The information and recommendations provided are based on the images presented by the referring veterinarian/sonographer. No evaluation can be communicated regarding pathology that was not visible in the image/video clips provided.

Thank you for this referral. If the clinical or image interpretation does not parallel your findings or if I can be of any further assistance please contact me.

HOSPITAL NAME

New Bridge
Veterinary Practice

Nele Eley, DVM, Dr. med. vet., DipECVDI
European Specialist in Veterinary Diagnostic Imaging, Cert. Radiology,
Senior lecturer University of Giessen, Germany, Veterinary Faculty, Department of Radiology
Nele.Eley@sonopath.com

REFERRING VET

Dr. Abina Glennon

INVOICE

56319

DATE

1-23-23